Reduction of coronary flow reserve non-invasively determined by transthoracic Doppler echocardiography as a predictor of left anterior descending coronary artery stenosis

Luigi De Simone, Pio Caso, Sergio Severino, Antonello D Andrea, Ciro Mauro, Vittorio Monda, Nicola Mininni

Laboratory of Echocardiography, Department of Cardiology, Hospital Monaldi , Naples, Italy

Key words:
Color Doppler echocardiography; Coronary flow reserve; Echocontrast.

Background. **The aim of this study was to evaluate if a reduced coronary flow reserve determined by transthoracic echocardiography alone or combined with contrast agents may represent a predictive index of significant left anterior descending coronary artery (LAD) stenosis.**

Methods. **Thirty-four patients (mean age 59 – 9 years) undergoing coronary angiography for coronary artery disease were studied. Coronary stenosis was classified (according to visually determined percent narrowing) as severe (> 75%), moderate (40 to 75%) and mild (< 40%). Coronary blood flow velocities were recorded in each patient at baseline and after low-dose dipyridamole administration by use of a 3.5 MHz transducer with a machine equipped with second harmonic capability and non-directional color Doppler software. Coronary flow reserve was defined as the ratio of hyperemic to basal diastolic peak velocity.**

Results. **Adequate Doppler recordings in the LAD were obtained by transthoracic echocardiography in 26/34 patients (76%); the infusion of Levovist® allowed for the visualization of LAD flow in a further 7 patients, with an overall feasibility of 97%. Coronary flow reserve was significantly higher in the group of patients with mild coronary lesions (2.3 – 0.3) than in patients with moderate (1.68 – 0.29, p = 0.0004) or severe (1.49 – 0.39, p = 0.0005) LAD stenosis.**

Conclusions. **By use of transthoracic echocardiography combined with contrast agents it is possible to visualize blood flow velocities in the LAD and to evaluate coronary flow reserve after dipyridamole infusion with a non-invasive approach. Combined with angiographic findings, this diagnostic approach could be useful in giving additional information to assess the functional significance of a stenotic coronary lesion.**

(Ital Heart J 2000; 1 (4): 289-294)

Received February 3, 2000; revision received March 29, 2000; accepted March 31, 2000.

Address:

Dr. Luigi De Simone

Via D. Fontana, 194
80131 Napoli
E-mail:
lmdesimo@jumpy.it

Introduction

Coronary flow reserve (CFR) represents the capability of the coronary apparatus of increasing blood flow under circumstances involving increased metabolic needs[1,2]. CFR can be reduced in two main conditions: the presence of significant coronary stenosis and abnormalities of microcirculation[3,4].

Nowadays, as CFR assessment is acquiring a relevant role as an accurate indicator of the functional significance of a coronary stenosis, several methods have been proposed to measure it. In previous studies CFR was usually determined by measuring the increase in coronary flow during a pharmacologically induced maximal vasodilation.

CFR evaluation during cardiac catheterization using Doppler intracoronary catheters represents the gold standard of this analysis[4-6]. Even if extremely accurate, this diagnostic approach is not widely used because of its relevant cost and invasivity[5].

Transesophageal Doppler echocardiography has been proposed as an alternative method for CFR assessment in the proximal left anterior descending coronary artery (LAD) in resting conditions and after pharmacological vasodilation[7,8]. Nevertheless, this technique, although in combination with contrast agents it shows a 69-89% success rate of visualization of coronary flow, presents only a modest acceptance for large scale assessment of CFR because of its semi-invasive nature.

Recent studies have shown for the first time the possibility of measuring CFR in a totally non-invasive way using transthoracic Doppler echocardiography (TTDE)[9-11]. A strict correlation between coronary flow reserve obtained with this non-invasive approach and Doppler intracoronary measurements has recently been assessed[6,12]. Furthermore, there was an excellent agreement for the identification of significant LAD stenosis between a CFR cut-off value of 1.8-2 ratio calculated by invasive Doppler wire measurement, and a CFR cut-off point of 2 ratio non-invasively determined by TTDE[13,14].

The aim of our study was to analyze the success rate of TTDE alone or in combination with contrast agents in the detection of CFR in the distal portion of the LAD, and to evaluate if a reduced CFR, determined in a non-invasive way, may represent a predictive index of LAD stenosis.

Methods

Patients. Thirty-four consecutive and non-selected patients (31 males, 3 females, mean age 59 – 9 years) undergoing coronary angiography for suspected or known coronary artery disease were studied. The underlying cardiac diseases were: previous (> 6 months) antero-septal myocardial infarction in 11 patients, previous (> 6 months) inferior myocardial infarction in 6 patients, unstable angina in 6 patients, stable angina in 10 patients, and hypertrophic cardiomyopathy in 1 patient. All drugs with a cardiovascular effect were withdrawn the day before the echocardiographic study.

All patients were informed of the purpose of the study and gave informed consent.

Transthoracic echocardiography. Echocardiographic examinations were performed with an Acuson Sequoia ultrasound system (Acuson Corporation, Mountain View, CA, USA), using a transducer with second harmonic capability (1.7 MHz transmitting and 3.5 MHz receiving).

The Sequoia ultrasound machine was equipped with software for non-directional Doppler, with properties of color Doppler modified setting the velocity range between 12 and 24 cm/s, thus reducing the pulse repetition frequency. Unlike traditional Doppler, non-directional Doppler was independent of the direction but dependent on the quantity of blood flow in the vessel analyzed. Compared to traditional Doppler echocardiography, this method is less influenced by the aliasing and also more sensitive in detecting low flow velocities and reduced blood volumes.

The visualization of the distal portion of the LAD was performed using a modified foreshortened 2-chamber view obtained by sliding the transducer superiorly and medially from an apical 2-chamber position, in order to reach the best alignment to the interventricular sulcus[10-14]. Subsequently, coronary blood flow in the distal portion of the LAD was searched for under the guidance of color Doppler flow mapping over the epicardial part of the anterior wall (Fig. 1).

A first attempt to record LAD flow was made in all patients using a 3.5 MHz phased-array transducer with second harmonic capability. Our choice to use a low-frequency probe was related to the possibility of utilizing an echo-enhancing agent to improve the Doppler signal in patients without an adequate color-coded blood flow[12,16]. As several patients in our study showed a poor acoustic window, the use of a 3.5 MHz rather than a 7 MHz transducer allowed a better evaluation of the coronary flow Doppler signal. The contrast agent used in our study was Levovist[fi] (SHU-508A, Schering AG, Berlin, Germany a suspension of galactose and fatty acid in sterile water), administered by an infusion pump into the right cubital vein, at a concentration of 300 mg/ml and at an infusion rate of 1 ml/min[10,12,17].

With the sample volume positioned on the color signal of the LAD, the spectral Doppler of the LAD flow showed the characteristic biphasic flow pattern with a larger diastolic and a smaller systolic component (Fig. 2A).

Study protocol. Coronary blood flow velocities were recorded in each patient under color-guided pulsed wave Doppler at baseline and after dipyridamole administration (0.56 mg/kg over 4 min). All patients had continuous heart rate, blood pressure and ECG monitoring. The following coronary flow velocity parameters were recorded at baseline and after dipyridamole infusion: systolic and diastolic peak velocities; systolic and diastolic velocity-time integrals. For each parameter, the three highest spectral Doppler signals were averaged. CFR was defined as the ratio of hyperemic to basal diastolic peak velocity. Normal CFR was defined as > 2.0 on the basis of previous studies[10-14].

All images were recorded on a magneto-optical disk

Figure 1. *A modified foreshortened 2-chamber view, used to obtain the best alignment to the interventricular sulcus. Color Doppler flow mapping in the interventricular sulcus* (white arrow) *allows for the visualization of the distal left anterior descending coronary artery* (yellow arrow), *identified as a red diastolic jet. LV = left ventricle.*

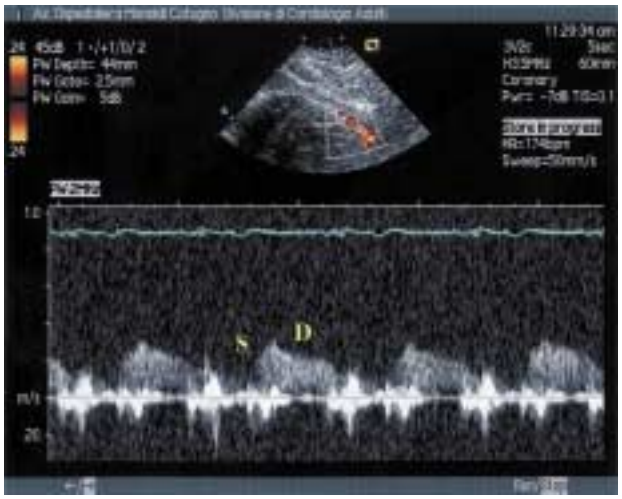

A

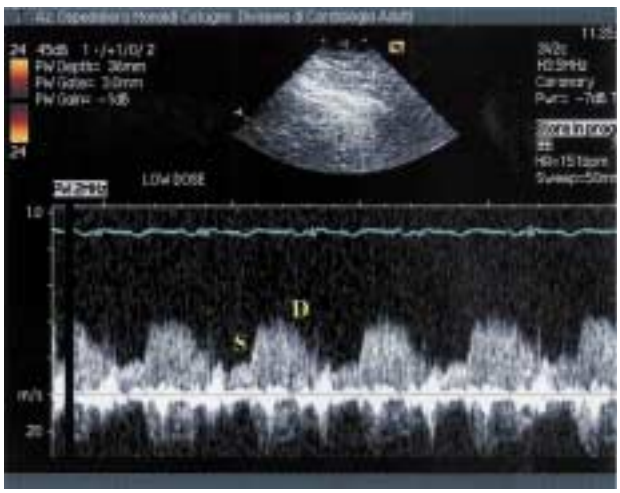

B

Figure 2. *Echo-Doppler analysis of the left anterior descending coronary artery flow at baseline* (A) *and during dipyridamole-induced hyperemia* (B). *The coronary flow appears predominant during the diastolic phase of the cardiac cycle. D = coronary diastolic flow; S = coronary systolic flow.*

and analyzed later by two observers who were blinded to clinical and angiographic results. Measurements were made off-line by use of the built-in calculation package of the ultrasound machine.

Coronary angiography. Coronary angiography was performed within a week of echocardiographic study by standard Judkins technique. Coronary arteries were examined by using multiple projections and stenoses were classified according to quantitative angiography as severe (> 75%), moderate (40 to 75%) and mild to no angiographic stenosis (< 40%). All coronary angiograms were blindly read.

Statistical analysis. Statistical analyses were performed by a commercially available statistical package. Data were expressed as mean values – SD. Student s paired t test was used for statistical analysis. A p value of < 0.05 was considered statistically significant. Sensitivity and specificity for CFR as a predictor of significant coronary stenosis were calculated in the traditional manner.

Intraobserver variability was calculated and expressed as the SD of the difference of the two readings divided by the average value. To determine interobserver variability, the average value of the first observer was compared with the reading of the second. Observer variability was analyzed by a paired Student s t test. A probability level of < 0.05 was considered statistically significant.

Results

On the basis of coronary angiography results, patients were divided into three groups:

Group 1 consisted of 13 patients (all males, mean age 60 – 10 years) with LAD stenosis > 75%. In this group, 8 patients had isolated LAD stenosis, 2 patients also had right coronary stenosis, and 3 patients had three-vessel coronary artery disease;

Group 2 was composed of 6 patients (5 males, 1 female, mean age 59 – 9 years), with LAD stenosis between 40 and 70%. In this group, 4 patients had isolated LAD stenosis and 2 patients had also right coronary stenosis;

Group 3 consisted of 14 patients (12 males, 2 females, mean age 59 – 9 years) with mild to no angiographic LAD stenosis. In this group, 4 patients had isolated right coronary stenosis; 2 patients had isolated circumflex coronary stenosis; 6 patients had undergone percutaneous angioplasty of the LAD at least 1 month before and the angiographic control did not underline hemodynamically significant lesions; 1 patient with stable angina and 1 patient with hypertrophic cardiomyopathy had no angiographic stenosis.

Visualization of coronary flow. Under the guidance of color Doppler flow mapping, adequate spectral Doppler recordings of coronary flow in the distal portion of the LAD were obtained by TTDE + second harmonic imaging in 26/34 patients (76%) over a distance of 1 cm. The infusion of Levovist® allowed for the visualization of the LAD flow in a further 7 patients. In 1 patient, despite the infusion of contrast agent, blood flow velocity during dipyridamole vasodilation was not achieved. In all, the feasibility of CFR evaluation was 97%.

Dipyridamole infusion. The variations of parameters evaluated in the three study groups, produced by dipyridamole infusion, are summarized in table I.

Neither major adverse reactions nor anginal symptoms occurred in any patients. Systolic and diastolic blood pressure did not change at all. No patient showed ECG modifications after low-dose dipyridamole infusion.

Determination of coronary flow reserve. Blood flow

Table I. Clinical and echo-Doppler data of the three patient groups at baseline and after dipyridamole-induced hyperemia.

	Group 1 (n=12)			Group 2 (n=6)			Group 3 (n=14)		
	Baseline	Dipyridamole	p	Baseline	Dipyridamole	p	Baseline	Dipyridamole	p
Age (years)	60 – 10			59 – 9			59 – 9		
Heart rate (b/min)	75 – 7	90 – 4	0.0001	62 – 13	82 – 14	0.02	67 – 11	83 – 13	0.002
DPV (m/s)	0.43 – 0.18	0.62 – 0.24	0.05	0.34 – 0.05	0.58 – 0.2	0.01	0.35 – 0.12	0.79 – 0.26	0.0005
SPV (m/s)	0.26 – 0.12	0.2 – 0.06	NS	0.22 – 0.03	0.32 – 0.07	0.009	0.21 – 0.07	0.43 – 0.18	0.0004
DVI (m)	0.15 – 0.05	0.19 – 0.06	NS	0.14 – 0.04	0.2 – 0.02	0.0085	0.14 – 0.05	0.24 – 0.06	0.0007
SVI (m)	0.06 – 0.03	0.08 – 0.03	NS	0.05 – 0.01	0.07 – 0.02	0.05	0.04 – 0.02	0.09 – 0.03	0.0001
CFR	1.49 – 0.39			1.68 – 0.29			2.3 – 0.3		

CFR = coronary flow reserve (as ratio between DPV after dipyridamole infusion and DPV at baseline); DPV = diastolic peak velocity; DVI = diastolic velocity-time integral; SPV = systolic peak velocity; SVI = systolic velocity-time integral.

velocities were similar in the three groups at baseline. However, after dipyridamole infusion blood flow velocities increased (Fig. 2B) more in Group 3 than in Group 2 and Group 1 (Table I).

As a result, CFR, assessed in 33/34 patients in whom the identification of the flow was achieved, was significantly higher in Group 3 than in Group 2 (2.3 – 0.3 vs 1.68 – 0.29, p = 0.0004) and Group 1 (2.3 – 0.3 vs 1.49 – 0.39; p = 0.0005).

Identification of significant LAD stenosis. Considering a cut-off point of CFR < 2 for the detection of significant LAD stenosis, in our population we correctly identified 12/13 significant stenoses in Group 1 (92%); in Group 2, 5/6 patients (83%) had a CFR value < 2; in Group 3, only 1/13 patients (7%) had a CFR < 2.

Therefore, a CFR < 2 had a sensitivity of 92% and a specificity of 72% for the presence of significant (> 75%) LAD stenosis.

Interobserver and intraobserver variability. Intraobserver and interobserver variability for the measurement of Doppler velocity recordings (diastolic and systolic peak velocities, diastolic and systolic velocity-time integrals) were 3.9 and 5.3% respectively.

Discussion

Echo-Doppler assessment of coronary flow. Recent use of the last generation ultrasound systems, with a significant improvement in spatial resolution, allowed the non-invasive identification of structures that, although located a few centimeters under the anterior wall of the chest, were previously too small to be visualized. This is the case of the distal segment of the descending anterior coronary artery, which usually presents a superficial course, along the interventricular sulcus[13,14].

A further improvement in the non-invasive visualization of the distal segment of the LAD derived from the use of both second harmonic technology and intravenously injected echocontrast agents, that, combined together, allow optimal detection of coronary flow in most cases, improving Doppler signal-to-noise ratio in coronary arteries[10-14].

Once the distal segment of the LAD is identified, by use of the sample volume of pulsed wave Doppler within the vessel lumen, it is possible to analyze the coronary artery flow, that presents a biphasic pattern at rest (Fig. 1), with a smaller systolic and a greater diastolic component[4,19,20]. This physiological pattern expresses lower coronary resistance and a better gradient of pressure between the aorta and the left ventricle during the diastolic phase of the cardiac cycle.

In accordance with previous studies[6,12], in our personal experience we observed a higher success rate of non-invasive visualization of the distal portion of the LAD using a 3.5 MHz probe with second harmonic capabilities rather than a 7 MHz transducer. This is the result of the use of both new color Doppler software of Acuson Sequoia, whose color Doppler properties were modified setting the velocity range between 12 and 24 cm/s, and of second harmonic technology, that allowed a 76% success rate of visualization of LAD flow. Therefore, in our study, the use of non-directional Doppler alone allowed for an adequate visualization of the LAD flow in a large percentage of patients, in contrast to previous studies[9,12], which usually used echo-enhancing agents in all patients. On the other hand, the use of an intravenously injected echocontrast agent such as Levovist[fi] further improved the success rate of CFR assessment, with a final value of 97%.

Coronary flow reserve analysis. As shown by other authors[4-6,21,22], various methods have previously been used to assess CFR. However, they were either invasive (Doppler flow wire, selective catheterization of the coronary sinus), semi-invasive (transesophageal echocardiography), or highly expensive (positron emission tomography). Conversely, CFR evaluation by TTDE combined with second harmonic imaging is a totally non-invasive, easily repeatable and non-expensive technique, largely used now in many echo

laboratories.

In our study we chose intravenous dipyridamole rather than other coronary vasodilators to induce hyperemia during CFR assessment for two main reasons. First, dipyridamole is less expensive and more readily available than other vasodilators such as adenosine. Second, even if dipyridamole infusion usually induces maximal coronary flow velocities later than adenosine (dipyridamole 287 – 101 s; adenosine 55 – 34 s), the vasodilatory effect is more persistent[23]. Since in the study we limited our use of the echo contrast enhancer to 7 patients (24%), the prolonged coronary vasodilation allowed for an accurate detection of the coronary flow in all patients.

In accordance with previous studies[10-14], a CFR value < 2 was able to identify in our population a significant LAD stenotic lesion (> 75%) in 12/13 patients, while a CFR > 2 identified 93% of patients without a significant LAD stenosis.

Although the differences among basal coronary velocities of the three groups were not significant, we evidenced a trend versus higher diastolic velocities at baseline in patients with significant LAD stenosis (Group 1). This fact may be the result of reduced resistance of the microcirculatory bed that could counterbalance the increased resistance to flow at rest caused by the stenosis, but limits its capability of further increasing flow during infusion of a vasodilating agent[2,24].

Of interest, in the group of patients with moderate LAD stenosis, the mean value of CFR was significantly lower than in the group without significant LAD lesions, while the differences between Group 2 and Group 1 were not significant: there is an overlapping value between the other two groups. However, the concern regarding the approach of this study is to compare a functional variable such as CFR with morphologic criteria such as a visually determined percent narrowing of a sing le vessel. Since it is generally accepted that decisions concerning coronary interventions should be combined with the evidence of cardiac ischemia[25,26], the use of coronary physiologic data such as CFR[3], in addition to coronary angiography and provocative stress tests, may be useful to facilitate clinical evaluation. Therefore, the assessment by TTDE of a CFR value < 2 in 5/6 patients of Group 2 gave a more severe functional significance than the anatomical one provided by angiography to the coronary stenosis.

As a result, CFR evaluation, combined with morphological information given by angiography, may be useful to evaluate the therapeutic approach also of coronary lesions considered hemodynamically non-significant.

Future advances. Non-invasive assessment of CFR by TTDE + second harmonic imaging might represent a useful technique to follow up patients undergoing coronary angioplasty to the LAD. In our study population, 6 patients underwent coronary angioplasty to the LAD, and a periodical check of their non-invasively determined CFR is being performed.

The administration of a second dose (0.84 mg/kg) of dipyridamole at the end of the CFR evaluation might allow for the completion of the standard protocol of pharmacological stress echocardiography, thus providing new information about myocardial wall motion also in segments independent of the LAD. As a result, a new echocardiographic pharmacological stress test protocol might be performed, able to analyze not only left ventricular wall motion abnormalities, but also the functional significance of a coronary lesion.

Study limitations. Our population included a large number of patients with coronary artery disease, and only one patient with hypertrophic cardiomyopathy. In this patient CFR might be impaired as a result of a microcirculatory bed disease, which could limit coronary flow increase after infusion of a vasodilating agent. On the other hand, 2 patients of Group 2 with previous myocardial infarction, despite the presence of a non-significant (< 70%) coronary stenosis, showed a reduced CFR, which may be due to a post-necrotic microcirculatory impairment[27,28].

CFR assessment can be invalidated if measurements are performed at the stenosis site or in a collateral branch.

Comparative, invasive data on CFR using Doppler sensor-tipped angioplasty guide wires were not performed. Nevertheless, initial comparison has already been assessed by others[11], showing a close agreement between non-invasive and invasive measurements. On the other hand, non-invasive CFR evaluation could underestimate CFR values obtained by Doppler flow wire in the case of large θ ang les. Therefore, it is essential for correct assessment of CFR to achieve a θ ang le < 30 , or, if larger, to keep it constant during the exam at baseline and after dipyridamole infusion. In fact, for the purpose of CFR evaluation, the absolute velocity was not needed because CFR was a ratio between 2 velocities. Furthermore, in our study there was no significant difference between the θ ang les at baseline and during induced vasodilation.

In conclusion, by use of TTDE equipped with non-directional Doppler combined with second harmonic imaging it is possible to:

visualize blood flow velocities in the LAD with or without intravenous contrast enhancement using a non-invasive approach;

evaluate CFR in the LAD as the ratio of blood velocity flow at baseline and after low-dose dipyridamole administration (0.56 mg/kg over 4 min);

give additional information in assessing the functional significance of a stenotic lesion in the epicardial vascular bed of the LAD.

Combined with coronary angiographic findings, this diagnostic approach could be useful not only in planning the further invasive or non-invasive treatment of LAD stenosis, but also in estimating its long-term

prognosis.

Acknowledgments

The authors are indebted to Mrs. Maria Bocchetti, Mr. Antonio Capone, Mr. Luigi Girella and Mr. Francesco Saverio Vitiello for their excellent nursing and technical support during the study protocol.

References

1. Gould KL, Lipscomb K, Hamilton GW. Physiological basis for assessing critical coronary stenosis. Instantaneous flow response and regional distribution during coronary hyperemia as measures of coronary flow reserve. Am J Cardiol 1974; 33: 87-94.
2. Hoffman JIE. Maximal coronary flow and the concept of coronary vascular reserve. Circulation 1984; 70: 153-9.
3. White CW. Clinical applications of Doppler coronary flow reserve measurements. Am J Cardiol 1993; 71: 10D-16D.
4. Ofili EO, Labovitz AJ, Kern MJ. Coronary flow velocity dynamics in normal and diseased arteries. Am J Cardiol 1993; 71: 3D-9D.
5. Graham SP, Cohen MD, Hodgson JM. Estimation of coronary flow reserve by intracoronary Doppler flow probes and digital angiography. Cathet Cardiovasc Diagn 1990; 19: 214-21.
6. Caiati C, Montaldo C, Zedda N, et al. Validation of a new non-invasive method (contrast-enhanced transthoracic second harmonic echo Doppler) for the evaluation of coronary flow reserve. J Am Coll Cardiol 1999; 34: 1193-200.
7. Iliceto S, Marangelli V, Memmola C, Rizzon P. Transesophageal Doppler echocardiography evaluation of coronary blood flow velocity in baseline conditions and during dipyridamole-induced coronary vasodilation. Circulation 1991; 83: 61-9.
8. Kranidis AI, Patsilinakos S, Filippatos G, et al. Non-invasive evaluation of coronary reserve. Assessment of coronary reserve in patients with coronary artery disease by transesophageal-Doppler echocardiography. Int J Cardiol 1999; 68: 107-13.
9. Kenny A, Shapiro LM. Transthoracic high-frequency two-dimensional echocardiography, Doppler and color flow mapping to determine anatomy and blood flow patterns in the distal left anterior descending coronary artery. Am J Cardiol 1992; 69: 1265-8.
10. Caiati C, Aragona P, Iliceto S, Rizzon P. Improved Doppler detection of proximal left anterior descending coronary artery stenosis after intravenous injection of a lung-crossing contrast agent: a transesophageal Doppler echocardiographic study. J Am Coll Cardiol 1996; 27: 1413-21.
11. Lambertz H, Tries HP, Stein T, Lethen H. Noninvasive assessment of coronary flow reserve with transthoracic signal-enhanced Doppler echocardiography. J Am Soc Echocardiogr 1999; 12: 186-95.
12. Caiati C, Montaldo C, Zedda N, et al. A new non-invasive method for coronary flow reserve assessment: contrast-enhanced transthoracic second harmonic echo Doppler. Circulation 1999; 99: 771-8.
13. Hozumi T, Yoshida K, Akasaka T, et al. Noninvasive assessment of coronary flow velocity and coronary flow velocity reserve in the left anterior descending coronary artery by Doppler echocardiography. J Am Coll Cardiol 1998; 32: 1251-9.
14. Hozumi T, Yoshida K, Ogata Y, et al. Noninvasive assessment of significant left anterior descending coronary artery stenosis by coronary flow velocity reserve with transthoracic color Doppler echocardiography. Circulation 1998; 97: 1557-62.
15. Hildick-Smith DJR, Shapiro LM. Potential use of transthoracic echocardiography in the assessment of coronary flow reserve. J Am Soc Echocardiogr 1999; 12: 590-5.
16. Powers JA, Burns PN, Souquet J. Imaging instrumentation for ultrasound contrast agents. In: Nanda NC, Schlief R, Goldberg BB, eds. Advances in echo imaging using contrast enhancement. Dordrecht: Kluwer Academic Publishers, 1997: 139-70.
17. Kaul S. Myocardial contrast echocardiography. Circulation 1997; 96: 3745-60.
18. Iliceto S, Caiati C, Aragona P, et al. Improved Doppler signal intensity in coronary arteries after intravenous peripheral injection of a lung-crossing contrast agent (SHU 508A). J Am Coll Cardiol 1994; 23: 184-90.
19. Ross J Jr, Mintz RG, Chandrasekaran K. Transthoracic two-dimensional high frequency (7.5 MHz) ultrasonic visualization of the distal left anterior descending artery. J Am Coll Cardiol 1990; 15: 373-7.
20. Kenny A, Wisbey CR, Shapiro LM. Measurements of left anterior descending coronary artery flow velocities by transthoracic Doppler ultrasound. Am J Cardiol 1994; 73: 1021-2.
21. Marzullo P, Parodi O, Sambuceti G, et al. Residual coronary reserve identifies segmental viability in patients with wall motion abnormalities. J Am Coll Cardiol 1995; 26: 342-50.
22. Cullen JH, Horsfield MA, Reek CR, et al. A myocardial perfusion reserve index in humans using first-pass contrast-enhanced magnetic resonance imaging. J Am Coll Cardiol 1999; 33: 1386-94.
23. Rossen JD, Quillen JE, Lopez AG, et al. Comparison of coronary vasodilation with intravenous dipyridamole and adenosine. J Am Coll Cardiol 1991; 18: 485-91.
24. Hoffman JI. Transmural myocardial perfusion. Prog Cardiovasc Dis 1987; 29: 429-64.
25. Topol EJ, Nissen SE. Our preoccupation with coronary luminology: the dissociation between clinical and angiographic findings in ischemic heart disease. Circulation 1995; 92: 2333-42.
26. Kern MJ, De Bruyne B, Pijls NHJ. From research to clinical practice: current role of intracoronary physiologically based decision making in the cardiac catheterization laboratory. J Am Coll Cardiol 1997; 30: 613-20.
27. Kern MJ. Coronary physiology revisited: practical insight from the cardiac catheterization laboratory. Circulation 2000; 101: 1344-51.
28. Teiger E, Garot J, Aptecar E, et al. Coronary blood flow reserve and wall motion recovery in patients undergoing angioplasty for myocardial infarction. Eur Heart J 1999; 20: 285-92.