Images in cardiovascular medicine

Morphologic changes in left ventricular thrombus in a patient with acute anterior myocardial infarction. Assessment with contrast echocardiography

Pasquale G. Gianfagna, Luigi P. Badano, Marika Werren, Paolo M. Fioretti

Cardiology Unit, Cardiovascular Science Department, Hospital "S. Maria della Misericordia", Udine, Italy

(Ital Heart J 2001; 2 (2): 152-153)

Received July 11, 2000; revision received December 4, 2000; accepted December 13, 2000.

Address:

Dr. Luigi P. Badano

Dipartimento di Scienze Cardiovascolari
U.O. Cardiologia
A.O. "S. Maria della Misericordia"
Piazzale S. Maria della Misericordia, 15
33100 Udine
E-mail: lbadan@tin.it

The development of a left ventricular thrombus is relatively common after acute anterior myocardial infarction, particularly in patients not submitted to thrombolysis[1,2]. Once detected, a post-infarction thrombus must be followed to assess its morphologic evolution (owing to its relation with the risk of embolism, which is increased if the thrombus becomes protruding and highly mobile) and the effect of antithrombotic treatment[3,4].

Two-dimensional echocardiography is the technique of choice for the diagnosis and follow-up of post-infarction thrombi; however its sensitivity and accuracy in detecting the morphological changes of left ventricular thrombi, especially when they are located at the apex, are suboptimal, despite the continued progress in diagnostic echocardiography such as the use of second harmonic imaging and high-frequency transducers[5,6]. Contrast echocardiography may represent a novel technique for the detection and morphologic follow-up of left ventricular thrombi in patients with acute myocardial infarction[7,8].

Sixteen hours following the onset of symptoms, a 49-year-old man with a diagnosis of acute myocardial infarction complicated by congestive heart failure was transferred from a primary care hospital to the Coronary Care Unit of our department. On admission, the patient underwent coronary angiography that showed three-vessel coronary artery disease. He was submitted to primary angioplasty followed by implantation of a stent on the right coronary and mid-left anterior descending artery. Echocardiography revealed the presence of a dilated and rounded left ventricle with an aneurysm at the apex. The inferior wall, mid-anterior septum and mid-anterior wall were akinetic and the ejection fraction was 36%. The clinical course was complicated by pericarditis. Echocardiographic evaluation performed on day 4 using a Sonos 5500 ultrasound system (Agilent Technologies, Andover, MA, USA) with 1.8 to 3.6 MHz harmonic imaging capabilities suggested left ventricular apical thrombosis (Fig. 1A). In order to confirm the presence of the thrombus and to assess its extent, an echocontrast study (Levovist®, Schering, Berlin, Germany, 2.5 g i.v.) was performed. A large, stratified mural apical thrombus was clearly distinguishable (Figs. 1B and 1C). The patient was treated using intravenous heparin and oral anticoagulants. One week later, a new echocardiographic study showed a change in the morphologic characteristics of the thrombus which appeared reduced in size (Fig. 2A). Echocontrast injection made it easier to appreciate the fact that the thrombotic mass had become excavated and that its morphology had changed from mural to pedunculated (Fig. 2B). This significantly modified the risk of embolism[4]. At 1 month of follow-up, the apical thrombus could no longer be visualized at echocardiography and no symptom or clinical sign of peripheral embolism has been reported.

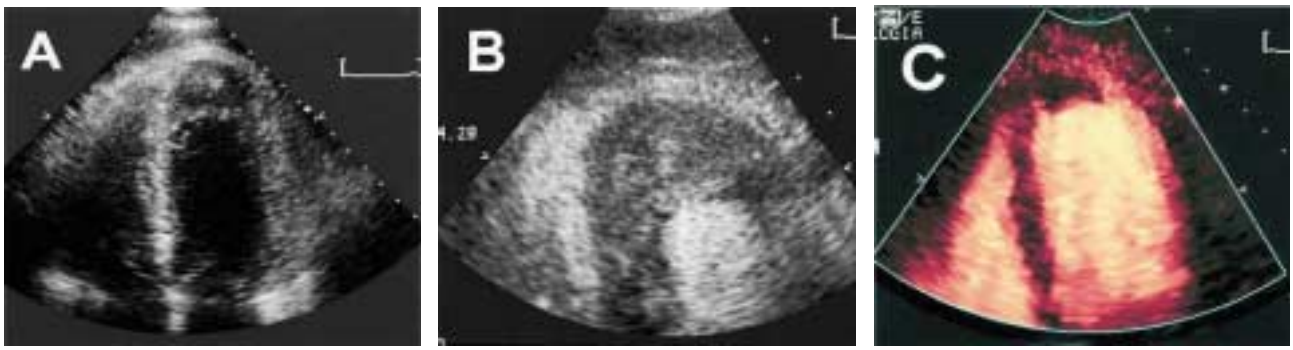

Figure 1. A: *two-dimensional apical 4-chamber view demonstrating a large, stratified thrombus filling the left ventricular apex.* B: *the thrombus is seen at gray scale contrast harmonic mode after Levovist injection.* C: *the thrombus is demonstrated at harmonic power Doppler mode after Levovist injection.*

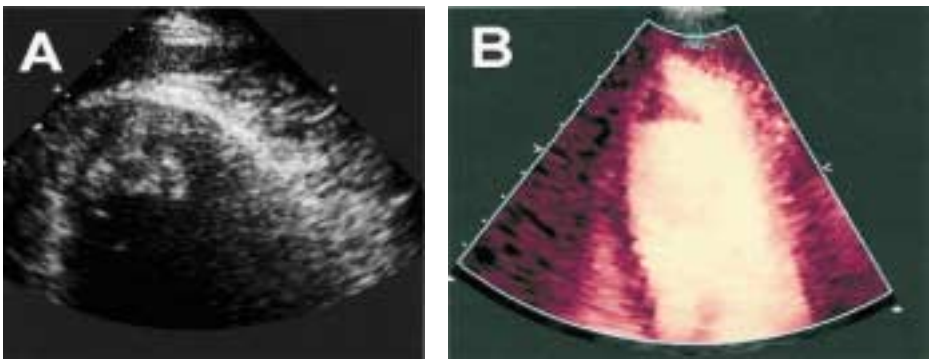

Figure 2. A: *two-dimensional apical 4-chamber view with apex magnification demonstrating a reduction in the size of the thrombotic mass recorded 8 days later.* B: *at harmonic power Doppler mode after Levovist injection the thrombus appeared clearly reduced in size and, due to thrombus mass excavation, its morphology changed from laminar to pedunculated.*

References

1. Asinger RW, Mikell FL, Elsperger J, Hodges M. Incidence of left ventricular thrombosis after acute transmural myocardial infarction. Serial evaluation by two-dimensional echocardiography. N Engl J Med 1981; 305: 297-302.
2. Vecchio C, Chiarella F, Lupi G, Bellotti P, Domenicucci S. Left ventricular thrombus in anterior myocardial infarction after thrombolysis. A GISSI-2 connected study. Circulation 1991; 84: 512-9.
3. Domenicucci S, Bellotti P, Chiarella F, Lupi G, Vecchio C. Spontaneous morphologic changes in left ventricular thrombi: a prospective two-dimensional echocardiographic study. Circulation 1987; 75: 737-43.
4. Domenicucci S, Chiarella F, Bellotti P, Bellone P, Lupi G, Vecchio C. Long-term prospective assessment of left ventricular thrombus in anterior wall acute myocardial infarction and implications for a rational approach to embolic risk. Am J Cardiol 1999; 83: 519-24.
5. Stratton JR, Lighty GW Jr, Pearlman AS, Ritchie J. Detection of left ventricular thrombus by two-dimensional echocardiography: sensitivity, specificity, and causes of uncertainty. Circulation 1982; 66: 156-66.
6. Bednarz JE, Spencer KT, Weinert L, Sugeng L, Mor-Avi V, Lang RM. Identification of cardiac masses and abnormal blood flow patterns with harmonic power Doppler contrast echocardiography. J Am Soc Echocardiogr 1999; 12: 871-5.
7. Asanuma T, Tanabe K, Yoshitomi H, Shimizu H, Okada S, Shimada T. Differential diagnosis of left ventricular mural thrombi by myocardial contrast echocardiography. Jpn Circ J 1999; 63: 50-2.
8. Thanigaraj S, Schechtman KB, Perez JE. Improved echocardiographic delineation of left ventricular thrombus with the use of intravenous second-generation contrast image enhancement. J Am Soc Echocardiogr 1999; 12: 1022-6.