Myocardial perfusion and metabolic changes induced by biventricular pacing in dilated cardiomyopathy and left bundle branch block: description of a case evaluated by positron emission tomography

Gianfilippo Neri, Pierluigi Zanco*, Riccardo Buchberger

*Department of Cardiology, ULSS 8 Veneto, Montebelluna (TV), *Department of Nuclear Medicine, ULSS 8 Veneto, Castelfranco Veneto (TV), Italy*

Key words:
Biventricular pacing; Heart failure; Positron emission tomography.

The effects of biventricular pacing on myocardial wall function are well known, but, at the moment, its real effects on myocardial metabolism are unclear. In patients affected by left bundle branch block, at positron emission tomography a septal defect of the uptake of 18F-fluorodeoxyglucose (FDG) was referred. There were no alterations in myocardial perfusion, suggesting possible metabolic damage. In this paper we report the case of a patient affected by dilated cardiomyopathy and left bundle branch block treated with a biventricular device. Biventricular pacing resolved both the wall motion alterations as well as the defect in FDG uptake present in the septal area. On the contrary, during biventricular pacing there were no modifications in myocardial perfusion as compared to basal evaluation.

(Ital Heart J 2001; 2 (6): 472-474)

© 2001 CEPI Srl

Received April 2, 2001; accepted April 6, 2001.

Address:

Dr. Gianfilippo Neri

Unità Operativa di Cardiologia Presidio Ospedaliero Via Montegrappa, 32 31044 Montebelluna (TV) E-mail: gianfilipponeri@tin.it

Introduction

Dilated cardiomyopathy (DCM) is characterized by structural abnormalities of the ventricular myocardium which affect both ventricular activation and mechanical contraction. The electrical activation may be delayed as a consequence of the pathological involvement of the conduction system or due to the inhomogeneous spread of excitation wave fronts across scarred tissue[1]. In recent studies, biventricular pacing resulted in improved ventricular synchrony and hemodynamic parameters[2-5]. In patients with left bundle branch block (LBBB), positron emission tomography (PET) documented a reduced uptake of 18F-fluorodeoxyglucose (FDG), a metabolic tracer, in the septum whilst, in the same area, perfusion, evaluated using 13N-ammonia (NH3) was preserved[6]. This phenomenon is called "reverse mismatch" and, at the moment, the underlying pathophysiology is not well understood.

In this paper our experience concerning the effects of biventricular pacing on myocardial perfusion and metabolism in a patient affected by DCM and LBBB is reported. Glucose uptake and myocardial perfusion were evaluated by PET before and during biventricular pacing, respectively using FDG and NH3 as tracers.

Case report

A 72-year-old male patient affected by DCM and LBBB with several episodes of heart failure despite optimal medical therapy with digoxin, furosemide, canrenone, ACE-inhibitors and carvedilol was admitted to our hospital. Coronary angiography documented no significant coronary stenosis and the ejection fraction was 31%. The atrioventricular delay was 193 ms and the QRS complex lasted 185 ms. We decided to implant a biventricular device in an attempt to improve the contractile synchrony and the left ventricular function.

Before implantation, the patient was submitted to PET evaluation performed using an ECAT EXACT scanner which allows simultaneous acquisition of 47 contiguous transaxial images, with total axial field of view of 16.2 cm.

At first, a transmission scan of 15 min was obtained for attenuation correction using retractable 68Ge rod sources. For emis-

sion studies, the tracers used were NH3 (dose 10 MBq/kg) injected at rest and FDG (dose 4 MBq/kg) injected after an oral glucose load coupled with intravenous insulin, in accordance with the method of Lewis et al.[7]. The emission scan started 45 min after the injection of 18F-FDG and lasted 15 min. For 13N-NH3 a 20 min dynamic acquisition was performed, starting immediately after the injection. To avoid artifacts due to misalignment, the repositioning of the patient in the scanner was checked using a cross-shaped low power laser beam and pen skin markers.

The short-axis and the vertical and horizontal long-axis slices, each 0.8 cm thick, were reconstructed using a Hanning filter (cut-off 1.18 cycle/cm) and corrected for attenuation. Visual analysis of the images was performed by two skilled observers. Their consensus was required. Moreover, taking the lateral wall as reference, the septal-to-lateral count rate density ratio of FDG was calculated in the midventricular horizontal long-axis slice (interpolated at a thickness of 1.6 cm) with the region-of-interest technique. The myocardial blood flow was also quantitatively evaluated in ml/m/g using the Patlak method, modified according to Choi et al.[8].

At visual analysis of the PET images, a severe septal defect of FDG uptake was found (Fig. 1), with a septal-to-lateral count rate density ratio value equal to 0.40, in the presence of a blood flow equal to 0.41 ml/m/g.

A Medtronic 2187 Attain lead (Medtronic Inc., Minneapolis, MN, USA) was positioned in a postero-lateral vein through the coronary sinus. The acute left ventricular threshold was 0.7 V. A Medtronic 5054 lead was inserted into the right ventricle and a Medtronic 5554 pre-shaped lead was inserted into the right atrium. The leads were connected with a Medtronic InSync model 8040 pulse generator to pace both the ventricles simultaneously.

The insertion and the activation of the device were associated with a 16 ms narrowing of the paced QRS complex (from the baseline value of 185 to 169 ms).

PET evaluation was repeated using the same techniques 3 weeks following the date of implantation. During biventricular pacing the FDG uptake in the septum had become normal (Fig. 1) and the septal-to-lateral count rate density ratio rose to 0.90 without relevant perfusion changes in the same area (0.46 ml/m/g).

Resynchronization of the septum during biventricular pacing was also confirmed using transthoracic echocardiography and color kinesis evaluation of endocardial movements.

Discussion

Multisite ventricular pacing has recently been proposed as an additional treatment for patients with severe heart failure and intraventricular conduction delay. The results of several studies using biventricular pacing showed an improvement in the patients' clinical conditions as evaluated by the NYHA functional class and the Minnesota Living with Heart Failure score, by the oxygen consumption during cardiopulmonary testing and the distance covered during the 6-min walk test[2-4].

Moreover, a recent paper of Nelson et al.[9] documented that biventricular pacing improves cardiac function at a lower energy cost in patients with DCM and LBBB.

We also know that patients with LBBB show the reverse mismatch phenomenon: good perfusion of the septum as evaluated by the uptake of NH3 in contrast with altered metabolism as evaluated by the uptake of FDG[6].

To better understand the underlying mechanism we evaluated our patient using PET in basal conditions and 3 weeks after the implantation of a biventricular device. Myocardial perfusion and metabolism were evaluated using the two tracers that are usually employed in nuclear medicine. FDG uptake in the septal area, severely reduced at basal evaluation, increased after implantation of the device, in contrast to no significant perfusion changes in the same area.

The underlying causes of this phenomenon are not well understood. It was suggested that reduced FDG uptake implies an inability, in the presence of LBBB, to use

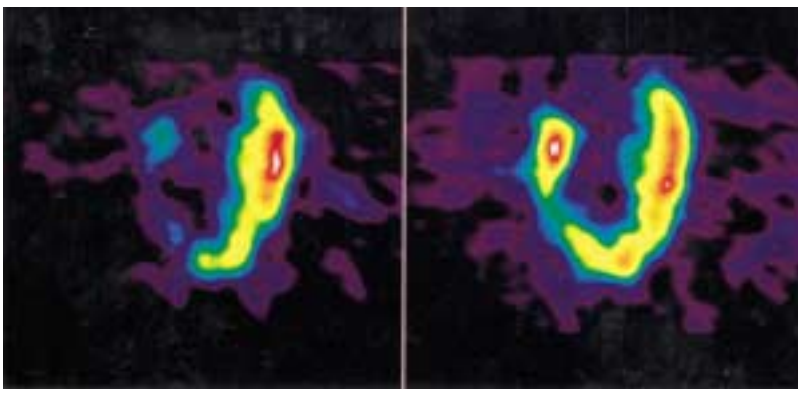

Figure 1. *18F-fluorodeoxyglucose positron emission tomography studies (mid-ventricular long-axis slices). An uptake defect in the septum may be clearly seen in the basal image* (left). *On the other hand, uptake was normal during biventricular pacing* (right).

glucose as a substrate in the septal region[10] and the normalization of FDG uptake with biventricular pacing could be due to better glucose utilization.

Moreover, the hypothesis of histological damage secondary to cardiomyopathy as a cause of altered septal uptake is no longer sustainable as it reverses with biventricular pacing.

It is likely that interference with the cellular membrane pumps, as suggested by Altehoefer[10], could explain the reduced FDG uptake in patients with LBBB. Our preliminary experience could suggest a normalization of this alteration induced by biventricular pacing.

In conclusion, our preliminary experience could suggest that in patients affected by DCM and LBBB, biventricular pacing not only improves myocardial wall function, but it also could induce a normalization of myocardial metabolism in the septum, without changes in perfusion. In particular, this may suggest a better use of glucose as a metabolic substrate.

References

1. Kerwin WF, Botvinick EH, O'Connel JW, et al. Ventricular contraction abnormalities in dilated cardiomyopathy: effect of biventricular pacing to correct interventricular dyssynchrony. J Am Coll Cardiol 2000; 35: 1221-7.
2. Cazeau S, Ritter P, Lazarus A, et al. Multisite pacing for end-stage heart failure: early experience. Pacing Clin Electrophysiol 1996; 19: 1748-57.
3. Blanc JJ, Etienne Y, Gilard M, et al. Evaluation of different ventricular pacing sites in patients with severe heart failure: results of an acute hemodynamic study. Circulation 1997; 96: 3273-7.
4. Auricchio A, Stellbrink C, Sack S, et al. The Pacing Therapies for Congestive Heart Failure (PATH-CHF) study: rationale, design, and endpoints of a prospective randomized multicenter study. Am J Cardiol 1999; 83: 130D-135D.
5. Leclercq C, Cazeau S, Le Breton H, et al. Acute hemodynamic effects of biventricular DDD pacing in patients with end-stage heart failure. J Am Coll Cardiol 1998; 32: 1825-31.
6. Zanco P, Desideri A, Mobilia G, et al. Effects of left bundle branch block on myocardial FDG PET in patients without significant coronary artery stenoses. J Nucl Med 2000; 41: 973-7.
7. Lewis P, Nunan T, Dynes A, Maisey M. The use of low-dose intravenous insulin in clinical myocardial F-18 FDG PET scanning. Clin Nucl Med 1996; 21: 15-8.
8. Choi Y, Huang SC, Hawkins RA, et al. A simplified method for quantification of myocardial blood flow using nitrogen-13-ammonia and dynamic PET. J Nucl Med 1993; 34: 488-97.
9. Nelson GS, Berger RD, Fetics BJ, et al. Left ventricular or biventricular pacing improves cardiac function at diminished energy cost in patients with dilated cardiomyopathy and left bundle-branch block. Circulation 2000; 102: 3053-9.
10. Altehoefer C. LBBB: challenging our concept of metabolic heart imaging with fluorine-18-FDG and PET? J Nucl Med 1998; 39: 263-5.