Coronary artery fistulas: clinical consequences and methods of closure. A literature review

Serban Balanescu, Giuseppe Sangiorgi, Serenella Castelvecchio, Massimo Medda, Luigi Inglese

Cardiac Catheterization Laboratory, Istituto Policlinico San Donato, San Donato Milanese (MI), Italy

Key words:
Cardiac surgery; Coronary fistula; Endoluminal intervention.

Coronary fistulas are uncommon anomalies of congenital and rarely iatrogenic etiology. Their clinical significance is mainly dependent on the severity of the left-to-right shunt they are responsible for. Symptoms, high-flow shunting and the occurrence of complications, only partially related to the magnitude of the shunt, are the main indications for their closure, especially in the adult population. Pediatric patients, even asymptomatic but presenting with electrocardiographic or chest X-ray abnormalities, should be treated in order to avoid the long-term complications related to the presence of the fistula. Treatment of adult asymptomatic patients with non-significant shunting is still a matter of debate. Surgery and direct epicardial or endocardial ligation were traditionally viewed as the main therapeutic method for the closure of coronary fistulas. Progress in the techniques of endoluminal intervention has led to fistula embolization using different devices including coils, balloons and chemicals. The success rate is good and the procedure-related morbidity acceptable.

(Ital Heart J 2001; 2 (9): 669-676)

Received June 28, 2001; revision received August 2, 2001; accepted August 9, 2001.

Address:

Dr. Serban Balanescu

Laboratorio di Emodinamica Istituto Policlinico San Donato Via Morandi, 30 20097 San Donato Milanese (MI) E-mail: smbala99@hotmail.com

Definition

Coronary artery fistulas are rare vascular anomalies that establish direct links between a large subepicardial coronary artery and a cardiac chamber or a large thoracic vessel. They most frequently drain into one of the ventricles, the pulmonary arteries, the coronary sinus, superior vena cava or pulmonary veins. Thus, their clinical significance derives mainly from the magnitude of the left-to-right shunt they are responsible for. Their etiology is most frequently congenital[1], but they may be occasionally attributable to cardiac trauma[2] or to iatrogenic factors such as therapeutic chest irradiation[3], surgery for congenital defects[4], coronary angioplasty[5] or repeated endomyocardial biopsies after heart transplantation[6]. The first published description of a coronary fistula was done in a pathological report dated 1865[7]. Biörck and Crafoord[8] performed the first successful surgical closure in 1947 and the first therapeutic embolization of abnormal thoracic vessels was performed in 1974 by Zuberbuhler et al.[9].

Their prevalence in the selected population of patients submitted to coronary angiography for any reason is low and ranges from 0.2 to 0.25%[10,11]. Fistulas are the most common congenital defects of coronary arteries[1], but represent only 0.4% of all congenital cardiac malformations[12]. Coronary fistulas are also found in association with various congenital heart diseases such as tetralogy of Fallot or pulmonary atresia with intact ventricular septum in which they can be associated with proximal coronary artery stenoses[13]. The fistulas may represent the only blood supply from the hypertensive right ventricle to a significant part of the left ventricle. A similar situation may be found as part of the hypoplastic left heart syndrome in infants with mitral stenosis and aortic atresia[14]. The management of these fistulas is not discussed in this review as they are most often surgically corrected at the time of intervention for the basic cardiac defect.

They are almost equally distributed in frequency between the right and left coronary arteries, but fistulas originating in the right coronary are slightly more frequent than those of the left coronary artery[15]. Occasionally bilateral coronary fistulas have been encountered (4 to 5% of all coronary fistula cases)[15,16].

Most of the fistulas originate proximally in the coronary tree, in the first segment of the involved coronary artery. Such an origin facilitates their closure by endoluminal or surgical intervention. Those located in the middle or distal segment of a coronary artery usually drain into the ventricular chambers.

Clinical significance, consequences

Most of the patients with coronary fistulas are asymptomatic and the anomaly is incidentally recognized at the time of coronary angiography performed for another reason.

Although they may be completely asymptomatic, patients with coronary artery fistulas may have significant abnormal findings at clinical examination, on standard ECG or at chest X-ray[4]. The most common clinical presentation is the finding of a continuous heart murmur, sometimes accompanied by signs of pulmonary congestion at X-ray and ECG signs of right ventricular volume overload.

Accumulating evidence suggests that the majority of patients do become symptomatic with advancing age, during the fifth or sixth decade of life[15,17], in relation to the slow, progressive enlargement of the fistula and to shunt augmentation. Only about one fifth of patients < 20 years of age and with coronary fistulas are symptomatic versus nearly two thirds of those > 20 years of age, with an overall incidence of symptoms of 39% in a series of 174 patients[15].

Complications of coronary fistulas include significant and sometimes serious conditions such as myocardial ischemia[18], pulmonary arterial hypertension[19], and congestive heart failure[20] due to left-to-right shunting. Other complications have been reported, including various arrhythmias[21,22], infectious endocarditis[20,23], and rupture with cardiac tamponade[20,24], but they are extremely rare.

Left-to-right shunting

The connection between the coronary tree and the pulmonary circulation due to the coronary fistula results in a left-to-right shunt of variable magnitude. In a majority of cases the shunt is small and has no hemodynamic consequences. In other cases, the severity of the shunt, expressed by a high pulmonary-to-systemic flow ratio, is responsible for hemodynamic abnormalities and the development of symptoms. Chronic volume overload of the right heart may lead to arterial pulmonary hypertension[19]. When long-term severe left-to-right shunting is present, congestive heart failure may occur[20]. The most frequently associated symptom is exercise dyspnea. This is due to high arterial pulmonary pressures and capillary engorgement with interstitial stasis.

There are no literature citations of Eisenmenger's syndrome occurring as a consequence of isolated untreated coronary fistulas, even when bilateral.

Myocardial ischemia

The relation between the presence of coronary fistulas and myocardial ischemia is well recognized[25-27]. Increased blood flow over the systemic-to-pulmonary fistula may lower the distal intracoronary diastolic pressure and result in ischemia by a "coronary steal phenomenon" in the absence of coronary artery disease[25,28-30]. Most of these patients develop exercise angina and much less frequently myocardial infarction[31,32].

Occasionally a coronary fistula may coexist with an atherosclerotic stenosis of the same coronary artery. Both contribute to the pathophysiology of myocardial ischemia[33]. Shear-induced intimal damage, caused by increased flow in the artery supplying the fistula, may result in the accelerated development of atherosclerosis in the involved vessel. Exercise angina is a common symptom and myocardial infarction has been occasionally reported[34,35]. The concomitant presence of coronary fistulas and coronary atherosclerosis has been described in patients who required surgery for both diseases[33].

The location of the coronary fistula with respect to the coronary stenosis may play a significant role in the pathophysiology of myocardial ischemia. In most published reports the fistula is located proximally to the coronary stenosis. In other cases the fistula is located distally to the stenosis and is variably associated with a right-to-left shunt because of the significant drop in the coronary pressure distal to the coronary lesion[24,36].

The mechanisms involved in the pathophysiology of ischemia with respect to fistula location are slightly different. In the first case, ischemia occurs because of the coronary steal phenomenon associated with the diminished coronary flow over the stenosis. In the second situation, ischemia is induced because of the reduction in coronary flow over the stenosis and myocardial irrigation with oxygen deprived blood from the pulmonary artery. Interestingly, in case of proximal coronary occlusion in the latter form of coronary-to-pulmonary fistula, the fistula may function as a bypass circuit that allows myocardial salvage and avoids infarction[24].

Indications for coronary fistulas treatment: to close or not to close?

Symptoms, complications and significant shunt are the main indications for the treatment of coronary artery fistulas[37]. There is a general consensus to close coronary fistulas in the presence of symptoms[15,38]. Fistula closure should always be attempted when associated with myocardial ischemia, even in the absence of coronary artery disease[25]. In case of traumatic coronary artery-cameral fistulas, that are uncommon sequelae of thoracic trauma, early surgical intervention is recommended in order to avoid long-term complications[39].

There is still controversy concerning fistula closure in asymptomatic patients. Since the potential long-term complications are serious, all those with moderate to severe shunting should be treated. Morbidity is minimal and results are good: patients with large, anatomically well identifiable fistulas can be referred to surgery (Fig. 1), even if asymptomatic[37]. Some investigators suggested elective surgical ligation even in the absence of symp-

toms and independently of shunt severity[15,20,40]. This is particularly true for pediatric patients in whom the lack of symptoms may be misleading and should not constitute the main criterion for therapy. The presence of significant clinical, ECG or roentgenographic abnormalities should be followed by fistula closure even in young asymptomatic patients[4]. Endoluminal closure may represent a valuable alternative in selected cases (Fig. 2).

Some authors argued in favor of closure in asymptomatic patients because they do develop symptoms with time, when the perioperative morbidity and mortality increase[41]. However, there is no clear indication to close a coronary fistula in asymptomatic adults or elderly subjects[37] with non-significant left-to-right shunting. In these patients the natural history of the disease has not been fully elucidated. There are published reports of spontaneous coronary fistula closure, although this is improbable in the majority of cases[42].

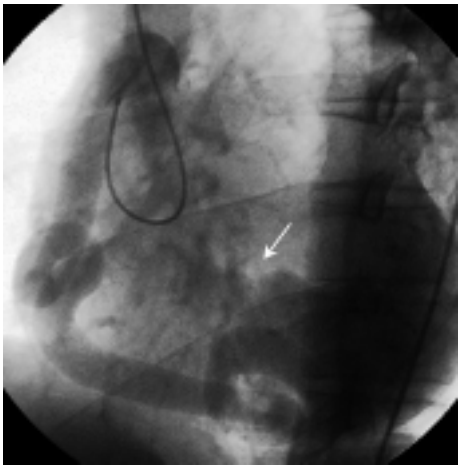

Figure 1. *Right coronary angiography of a 58-year-old man who presented with exercise-induced breathlessness and ECG signs of right ventricular volume strain. An aneurysmally dilated right coronary artery due to high volume overload in the presence of a fistula draining into the coronary sinus from the right coronary artery* (white arrow) *was observed. An endoluminal approach was not attempted owing to the large size of the fistula and which was therefore closed surgically with complete resolution of symptoms at short-term follow-up.*

Prior to the decision regarding the method of closure, surgical or percutaneous, the pathological presentation and precise anatomy of the fistula should be assessed by angiography. As most of these anomalies originate in the proximal vessel segments, as a single conduit that later develops into a maze of capillary vessels, they are easily accessible for endoluminal or surgical closure. Sometimes fistulas have multiple origins in the coronary artery and present as a complex, plexiform, diffuse vascular anomaly resembling hemangiomas (Fig. 3). In these cases fistula closure raises difficult technical problems for the surgeon or the interventionist.

Methods of closure: cut and sew or fill with steel?

Surgery. Soon after coronary fistulas were recognized surgical closure became the technique most widely employed for successful treatment[21]. There is an inherent risk of perioperative mortality of 2 to 4%[43,44] and of perioperative myocardial infarction of 3.6%[43] in adults. Perioperative complications are directly related to age: the incidence of complications reaches 23% for patients > 20 years whereas it is < 1% among those < 20 years[15]. Recent studies report a 100% closure rate with a 100% postoperative survival in pediatric populations[4].

Two techniques may be employed for definitive surgical closure of coronary fistulas: external ligation ("epicardial approach"), without cardiopulmonary bypass, and direct suture of the fistulous ostium from within the recipient chamber ("endocardial approach")[4]. A coronary artery bypass graft may occasionally be necessary following epicardial ligation of the fistulous vessel due to accidental closure of the main coronary vessel[39].

The surgical techniques are associated with a reduced incidence of fistula recurrence, mainly when direct endocardial ligation with cardiopulmonary bypass is used[37,45]. In a group of 21 patients, the incidence of angiographically confirmed long-term fistula recurrence was 16.6% for patients submitted to the endocardial approach and 22.2% for patients in whom an epicardial closure was performed, with a surprisingly high

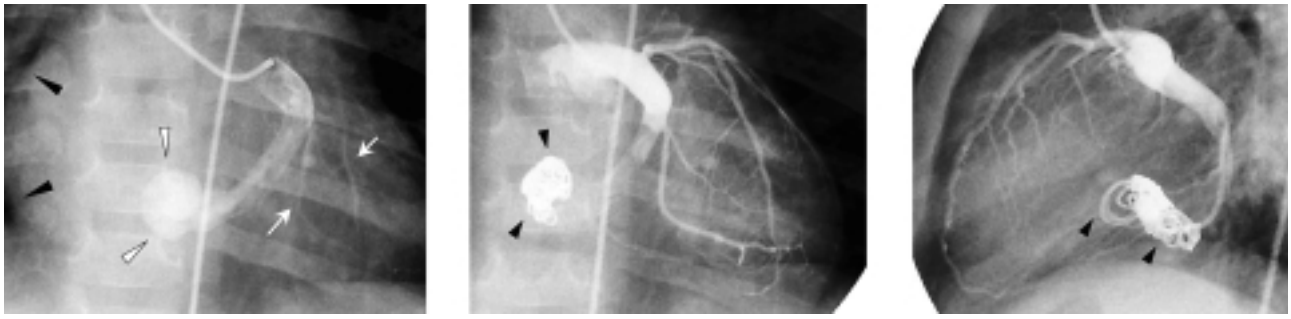

A B C

Figure 2. A: *right anterior oblique incidence showing a large fistula connecting the left coronary sinus of Valsalva with the right atrium. The fistula was totally opaque* (black triangles)*, and involved the left main trunk of a 12-year-old patient with a significant left-to-right shunt. The left anterior descending and the circumflex arteries* (white arrows) *are poorly opacified owing to the preferential flow to the fistula. An aneurysmal cavity* (white triangles) *is evident at the atrial end.* B *and* C*: right anterior oblique and left lateral incidence after full endoluminal fistula closure with multiple coils deployed in the aneurysmal cavity* (black triangles)*. Good opacity of the otherwise normal left anterior descending and circumflex arteries.*

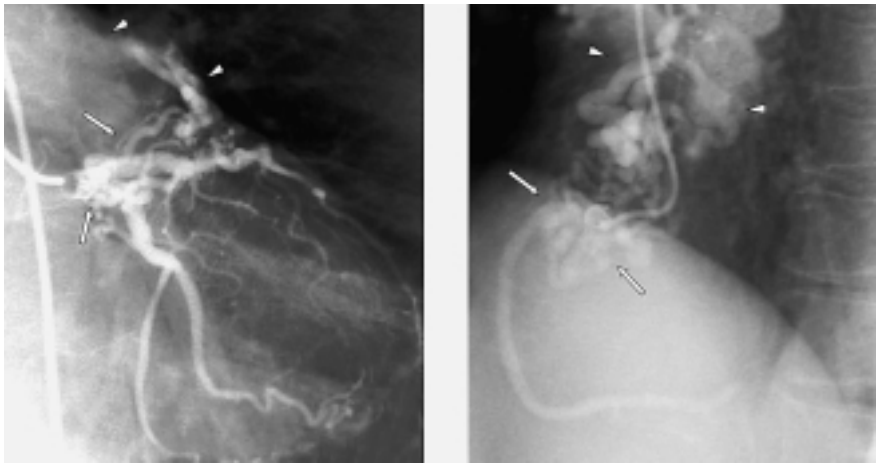

A B

Figure 3. *Coronary angiography of a 62-year-old woman with exercise angina and minor T wave abnormalities in the anterior ECG leads. Selective left main contrast injections show a complex coronary artery fistula with multiple origins in the left main, proximal left anterior descending and circumflex coronary arteries* (white arrows) *and draining into the pulmonary trunk* (white triangles) (A). *Another complex fistula was identified in the proximal segment of the right coronary artery* (white arrows) *also draining into the pulmonary artery* (white triangles) (B). *The pathological presentation of this type of fistula makes surgical or endoluminal closure extremely difficult.*

mean incidence of patency (19%)[37]. However, a randomized direct comparison of the therapeutic efficacy of surgery versus endovascular closure of coronary fistulas has not been performed yet.

Surgical ligation should be reserved for patients who are not suitable for endoluminal closure owing to the presence of a complex and distally located fistula, of adjacent vessels at risk, of a large fistula or in view of the subject's young age[4] and in case an associated intervention for the correction of other congenital defects or coronary artery bypass graft operation is required[40].

Endoluminal intervention. As technological progress and technical refinements allowed the successful accomplishment of complicated endoluminal interventions, some catheter-based methods were also designed for coronary fistula closure. They included detachable balloons, stainless steel and platinum coils or different chemicals, such as pure alcohol[46-49]. All catheter-based methods were conceived mainly to reduce the inherent risks associated with open-chest surgery, hospital stay and intervention-related costs[17,43,49].

Endoluminal closure should be performed in patients with a single proximal fistula origin, in case of advanced age and in the absence of other cardiac diseases necessitating surgery (coronary artery disease, other congenital heart diseases, etc.) (Fig. 4). Technical details that maximize the success rate include the ability to safely and firmly cannulate the origin of the fistula, the absence of large collateral vessels that would not be amenable to adequate embolization and a single narrow distal drainage of the abnormal vessel[4].

Coil embolization

The coils available in clinical practice are made of stainless steel or platinum and some of them have a fiber

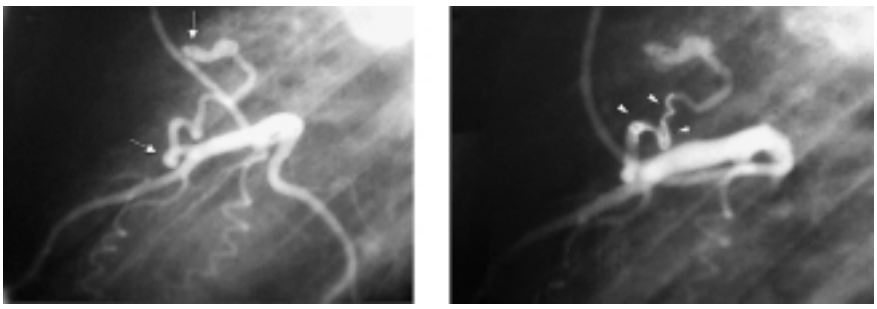

A B

Figure 4. *Left lateral angiographic incidence of the left coronary artery showing a single fistulous vessel emerging from the left anterior descending coronary artery and draining into the pulmonary artery* (white arrows) *in a 65-year-old woman presenting with medium threshold exercise angina and scintigraphic anterior wall reversible ischemia* (A). *Selective left anterior descending coronary artery contrast injections in the left lateral projection show persistent flow in the fistula after coil embolization* (white triangles) (B). *An exercise test and perfusion myocardial scintigraphy performed 3 months following the procedure were negative for ischemia, suggesting full late closure of the fistula by coil-induced thrombosis.*

design to increase thrombogenicity[50]. The first steel coils ever used were large (0.038”-0.035”), had to be deployed through large 5 or 6F catheters and could not be drawn back into the guiding catheter. All these characteristics limited their use to large, proximally located coronary fistulas and inadequate embolization was rather frequent. New interlocking detachable coils can be deployed through a 3F microcatheter (Tracker, Target Therapeutics, Cork, Ireland) co-axially introduced in a 5 or 6F coronary guiding catheter. The tracker can be advanced via a floppy 0.014” guidewire introduced in the native coronary artery and positioned inside the fistula[50]. Embolization can then be performed with appropriately sized coils, 10 to 20% larger than the diameter of the vessel as measured when occluded[51]. The interlocking detachable coils have a controlled release system consisting of a connection with the pusher. This system allows their retrieval in the tracker when necessary, even after deployment in the abnormal vessel[50].

In high-flow fistulas, temporary balloon occlusion of the proximal vessel may be necessary to allow coil deployment. In these cases a combination of large diameter coils and interlocking coils can be used (Fig. 2).

Gianturco coils have been used to percutaneously close coronary fistulas. The success rate was moderately good when these devices were used alone. In two small series of patients only 47% could be successfully treated with coils alone[47,51].

The use of coil embolization may be burdened by incomplete fistula closure: in a small group of patients, full suppression of abnormal flow was achieved in 92% of treated vessels, with a 23% rate of inadequate deployment of coils that necessitated snare retrieval[50]. Other studies reported a much lower success rate, around 40-50%[51]. Improper coil delivery may be associated with acute myocardial infarction and even death due to distal embolization in a large epicardial vessel[17]. Even high-flow coronary fistulas can be closed by coil deployment and surgery is not always needed[52,53] (Fig. 2).

Hybrid procedures, such as alcohol and coil embolization, have been reported by our group. Such procedures were resorted to with the purpose of reducing the probability of a residual shunt and the development of collateral feeding vessels after simple coil embolization and in order to increase procedural success (Fig. 5)[54].

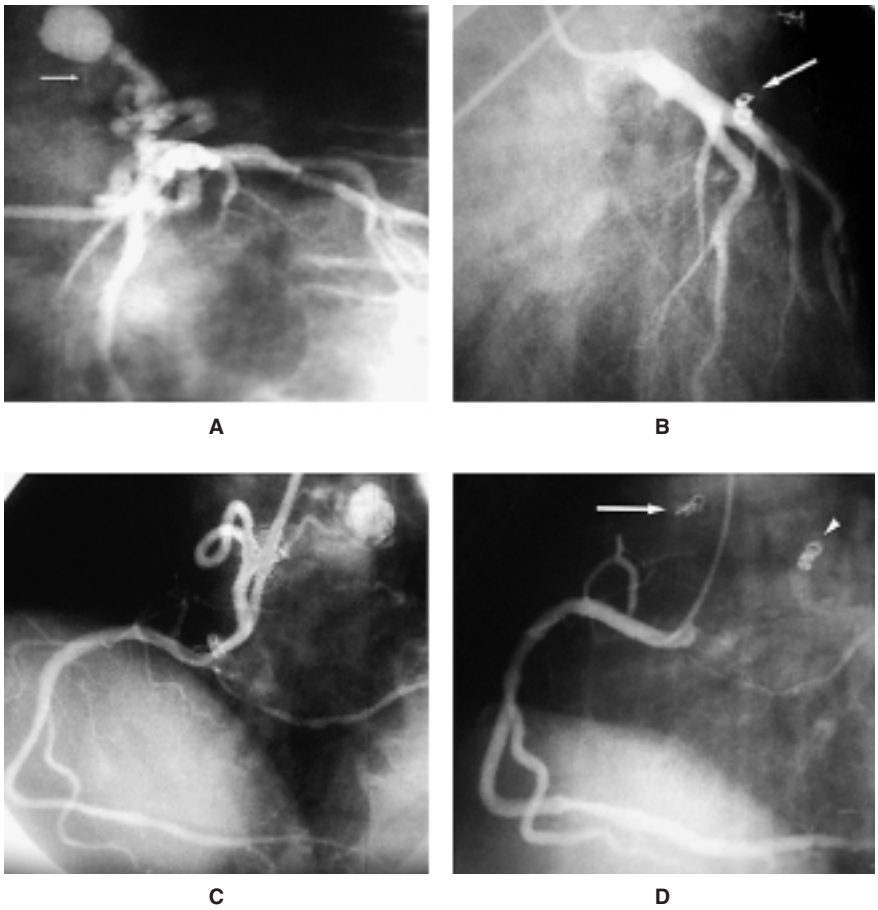

Figure 5. *Selective angiography of the left anterior descending and circumflex arteries in a 70-year-old patient presenting with myocardial ischemia. A tortuous fistula originating from the left main coronary artery and draining into the pulmonary artery* (white arrow) *is noted* (A). *After alcohol injection, multiple coils have been delivered into the mid part of the fistula with complete occlusion (coils,* white arrow) (B). *Right coronary artery angiography demonstrating a fistula originating from the proximal right coronary artery and draining into the right pulmonary artery in the same patient* (C). *Control angiography after coil deployment into the middle part of the fistula* (white arrow) *with complete exclusion of the left-to-right shunt* (D). *The coils used to close the fistula originating from the left coronary artery are also evident* (white triangle). *From Sangiorgi et al.[54], with permission.*

Other procedures

Alcohol injection has been used to occlude the first large septal branches in hypertrophic cardiomyopathy[55] or to close peripheral arteriovenous malformations[56]. Pure alcohol causes extensive endothelial damage by cell dehydration and precipitation of cytoplasmic proteins. Endothelial necrosis is followed by thrombosis determined by the activation of the coagulation cascade and platelet adhesion and aggregation in contact with media constituents. Alcohol-induced necrosis of the vessel wall may extend up to the level of the internal elastic lamina[57]. Technical considerations regard firm occlusion of the fistula origin with an appropriately sized over-the-wire balloon and injection of an alcohol volume approximately equal to that of the volume of contrast necessary in order to achieve full opacity of the fistula[58].

Some authors prefer detachable balloons to coils; these have to be precisely sized to the largest fistula diameter so as to safely close the abnormal communication[59]. In view of their ability to follow winding catheter courses without any recoil of the tip thus allowing precise positioning, their use is indicated in patients in whom the fistula has a very tortuous anatomy[51]. They should be filled with diluted contrast and not with a silicone polymer: if improperly delivered they can be deflated and safely retrieved using a snare, while silicone cannot be removed after it polymerizes[47]. Detachable balloons necessitate larger guiding catheters (8 or 9F) thus increasing the risk of vascular complications and are not suitable for pediatric patients[60].

There are some reports of closure of large congenital coronary arteriovenous fistulas using the Amplatz Duct Occluder[48,61] or the Bard PDA Umbrella[51]. This procedure is rarely technically possible and should be reserved to particular anatomical presentations. In case of coronary-cameral fistulas, it is preferable to deliver umbrella devices from the right ventricle in order to avoid damage of the artery[51]. The diameter of the umbrellas should be at least twice that of the opening into the right heart[51].

Covered stents

The so-called "covered stents" or "stent grafts" represent an alternative technique for closure of coronary fistulas.

The background for coronary fistula closure with a stent graft is derived from its successful use in treating serious complications of coronary angioplasty such as coronary rupture[62] or late aneurysm formation[63]. The unique quality of the stent graft is that it may build an artificial arterial wall hence allowing exclusion of aneurysms[64] or sealing of any vessel perforation[65,66].

An important limitation of stent graft implantation in coronary arteries is that these devices may occlude the lateral branches emerging from the target segment. This is particularly important in the left anterior descending coronary artery that gives origin to large septal or diagonal branches. In case of coronary fistulas, this disadvantage converts to a therapeutic target, since correct positioning of the stent may result in exclusion of the fistula. Another problem with the use of covered stents is the fact that this foreign body (stent and synthetic membrane), having a large surface, may predispose to acute closure and delayed endothelization[63].

Implantation of stent grafts to close coronary fistulas is presently reserved for those rare cases that concomitantly present with a fistula and a coronary stenosis in the same vessel segment. We have recently reported the case of a patient with early post-infarction angina who had a coronary-to-pulmonary artery fistula and atherosclerotic disease of the proximal left anterior descending coronary artery that were both treated by the deployment of a single ePTFE stent graft that covered both lesions (Fig. 6)[67]. A similar case has been presented by other authors[68].

Implantation of a covered stent to close a coronary fistula in the absence of atherosclerotic disease of the native vessel is not presently justified or accepted.

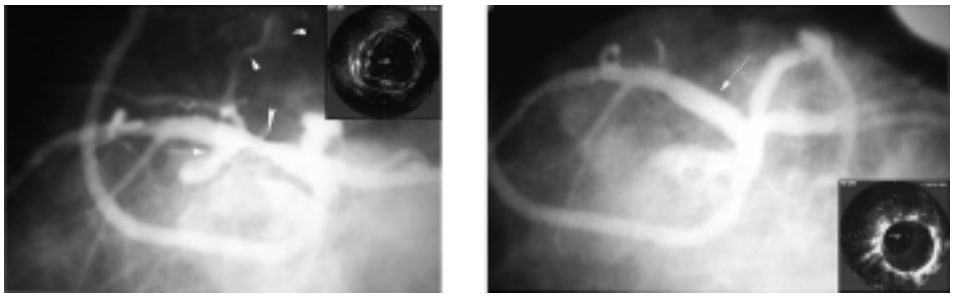

A B

Figure 6. *Left lateral projection* (A) *of the left coronary artery of a 47-year-old man who presented with early post-myocardial infarction angina. A stenosis in the proximal segment of the left anterior descending coronary artery is evident* (white large triangle) *and quantified as occupying 40% of the vessel lumen by intracoronary ultrasound examination* (small panel). *The fistula origin* (arrow) *with small branches emerging from it (small triangles) is shown. Control angiography after ePTFE covered stent deployment in the 90° left lateral and 30° caudal projections* (B) *shows complete occlusion of the fistula and lack of residual stenosis in the left anterior descending coronary artery. Full expansion of the stent graft was confirmed by intracoronary ultrasound* (small panel). *From Balanescu et al.[67], with permission.*

Conclusions

Fistulas are rare congenital or acquired, sometimes iatrogenic, anomalies of coronary arteries. The presence of symptoms, complications and a significant shunt are the main indications for coronary artery fistula closure. Treatment of asymptomatic patients with non-significant left-to-right shunt is still a matter of debate; the evolutive nature and potential complications of the lesion have been used by some authors as arguments in favor of treatment even for these patients. Surgery is presently indicated in young patients with lesion characteristics which make endoluminal closure inappropriate (complex anatomy with distal location, adjacent vessel at risk, large fistula) and in those who require concomitant surgery for other congenital heart disease or coronary artery bypass graft operation. Technical progress in interventional cardiology has allowed endoluminal closure in selected patients by a large variety of embolization methods with good success rates and an acceptable procedure-related morbidity. Percutaneous closure can be used in elderly patients with a single proximal fistula origin in the absence of concomitant cardiac disease necessitating surgical correction; it reduces the morbidity and mortality associated with open chest surgery, intervention related costs and hospital stay. Coils or detachable balloon embolization, alcohol or foam injection and Amplatz devices have all been used to close coronary fistulas with acceptable success and complication rates. Covered stents may represent a treatment alternative in those rare cases of coronary fistulas associated with adjacent atherosclerotic stenosis.

References

1. Levin DC, Fellows KE, Abrams HL. Hemodynamically significant primary anomalies of the coronary arteries: angiographic aspects. Circulation 1978; 58: 25-34.
2. Lowe J, Adams D, Cummings R, Wesly R, Phillips H. The natural history and recommended management of patients with traumatic coronary artery fistulas. Ann Thorac Surg 1983; 36: 295-305.
3. Benitez RM. Acquired coronary artery - pulmonary artery connection. Cathet Cardiovasc Diagn 1998; 45: 413-5.
4. Mavroudis C, Backer CL, Rocchini AP, Muster AJ, Gevitz M. Coronary artery fistulas in infants and children: a surgical review and discussion of coil embolization. Ann Thorac Surg 1997; 63: 1235-42.
5. Iannone L, Iannone D. Iatrogenic left coronary artery fistula-to-left ventricle following PTCA: a previously unreported complication with nonsurgical management. Am Heart J 1990; 120: 1215-7.
6. Henzlova M, Nath H, Bucy R, Bourge R, Kirklin J, Rogers W. Coronary artery to right ventricle fistula in heart transplant recipients: a complication of endomyocardial biopsy. J Am Coll Cardiol 1989; 14: 258-61.
7. Krause W. Uber den Ursprung einer akzessorischen A. coronaria aus der A. pulmonalis. Z Ration Med 1865; 24: 225.
8. Biörck G, Crafoord C. Arteriovenous aneurysm on pulmonary artery simulating patent ductus arteriosus Botalli. Thorax 1947; 2: 65-74.
9. Zuberbuhler J, Dankner E, Zoltun R, Burkholder J, Bahnson H. Tissue adhesive closure of aortic-pulmonary communications. Am Heart J 1974; 88: 41-6.
10. Effler DB, Sheldon WC, Turner JJ, Groves LK. Coronary arteriovenous fistulas: diagnosis and surgical management. Report of fifteen cases. Surgery 1967; 61: 41-50.
11. Baltaxe HA, Wixson D. The incidence of congenital anomalies of the coronary arteries in the adult population. Radiology 1977; 122: 47-52.
12. Davis J, Allen H, Wheller J, et al. Coronary artery fistula in the pediatric age group: a 19-year institutional experience. Ann Thorac Surg 1994; 58: 760-3.
13. Calder A, Co E, Sage M. Coronary arterial abnormalities in pulmonary atresia with intact ventricular septum. Am J Cardiol 1987; 59: 436-42.
14. Baffa J, Chen S, Guttenberg M, Norwood W, Weinberg P. Coronary artery abnormalities and right ventricular histology in hypoplastic left heart syndrome. J Am Coll Cardiol 1993; 20: 350-8.
15. Liberthson RR, Sagar K, Berkoben JP, Weintraub RM, Levine FH. Congenital coronary arteriovenous fistula: report of thirteen patients. Review of the literature and delineation of the management. Circulation 1979; 59: 849-54.
16. Baim DS, Kline H, Silverman JF. Bilateral coronary-pulmonary artery fistulae: report of five cases and review of the literature. Circulation 1982; 65: 810-5.
17. Dorros G, Thota V, Ramireddy K, Joseph G. Catheter-based techniques for closure of coronary fistulae. Catheter Cardiovasc Interv 1999; 46: 143-50.
18. St John Sutton MG, Miller GA, Kerr IH, Traill TA. Coronary artery steal via large coronary artery to bronchial artery anastomosis successfully treated by operation. Br Heart J 1980; 44: 460-3.
19. Davison PH, McCracken BH, McIlven DJS. Congenital coronary arterio-venous aneurysm. Br Heart J 1955; 17: 569-72.
20. Wilde P, Watt I. Congenital coronary artery fistulae: six new cases with a collective review. Clin Radiol 1980; 31: 301-11.
21. Sakakibara S, Yokoyama M, Takao A, Nogi M, Gomi H. Coronary arteriovenous fistula: nine operated cases. Am Heart J 1966; 72: 307-14.
22. McNamara JJ, Gross RE. Congenital coronary artery fistula. Surgery 1969; 65: 59-69.
23. Alkhulaifi A, Horner S, Pugsley W, Swanton R. Coronary artery fistulas presenting with bacterial endocarditis. Ann Thorac Surg 1995; 60: 202-4.
24. Castedo E, Oteo JF, Burgos R, et al. Coronary artery fistula as a bypass of a left anterior descending coronary artery stenosis. Ann Thorac Surg 1997; 64: 1813-4.
25. Kiuchi K, Nejima J, Kikuchi A, Takayama M, Takano T, Hayakawa H. Left coronary artery-left ventricular fistula with acute myocardial infarction, representing the coronary steal phenomenon: a case report. J Cardiol 1999; 34: 279-84.
26. Wolf A, Rockson SG. Myocardial ischemia and infarction due to multiple coronary-cameral fistulae: two case reports and review of the literature. Cathet Cardiovasc Diagn 1998; 43: 179-83.
27. Elhendy A, Nierop PR, Roelandt JR, Fioretti PM. Myocardial ischemia assessed by dobutamine stress echocardiography in a patient with bicoronary to pulmonary artery fistulas. J Am Soc Echocardiogr 1997; 10: 189-91.
28. Imperadore F, Moschini E, Volta G, Disertori M. Fistola artero-venosa coronarica congenita associata a dotto arterioso pervio: descrizione di un caso clinico e revisione della letteratura. Cardiologia 1997; 42: 525-8.
29. Roberts WC. Major anomalies of coronary arterial origin seen in adulthood. Am Heart J 1986; 111: 941-63.

30. Theman TE, Crosby DR. Coronary artery steal secondary to coronary arteriovenous fistula. Can J Surg 1981; 24: 231-6.
31. Hirose H, Takagi M, Miyagawa N, et al. Coronary atherosclerosis with dual coronary artery fistulas. Scand Cardiovasc J 1998; 32: 313-4.
32. Said SA, Landman GH. Coronary-pulmonary fistula: long-term follow-up in operated and non-operated patients. Int J Cardiol 1990; 27: 203-10.
33. Rangel A, Chavez E, Badui E, et al. Case report of association of congenital coronary fistulae with coronary atherosclerosis. Rev Invest Clin 1995; 47: 481-6.
34. McLellan BA, Pelikan PC. Myocardial infarction due to multiple coronary-ventricular fistulas. Cathet Cardiovasc Diagn 1989; 16: 247-9.
35. Yamabe H, Fujitani K, Mizutani T, Fukuzaki H. Two cases of myocardial infarction with coronary arteriovenous fistula. Jpn Heart J 1983; 24: 303-8.
36. Sathe S, Warren R, Vohra J, Skillington P, Hunt D. Coronary-pulmonary artery fistula arising distal to obstructive coronary lesions. Cardiology 1992; 80: 77-80.
37. Cheung D, Au W, Cheung H, Chiu C, Lee W. Coronary artery fistulas: long-term results of surgical correction. Ann Thorac Surg 2001; 71: 190-5.
38. Lowe JE, Oldham HN, Sabiston DC. Surgical management of congenital coronary artery fistulas. Ann Surg 1981; 194: 373-9.
39. Friesen C, Howlett J, Ross D. Traumatic coronary artery fistula management. Ann Thorac Surg 2000; 69: 1973-82.
40. Goto Y, Abe T, Sekine S, Iijima K, Kondoh K, Sakurada T. Surgical treatment of the coronary artery to pulmonary artery fistulas in adults. Cardiology 1998; 89: 252-6.
41. Schumacher G, Roithmaier A, Lorenz H, et al. Congenital coronary artery fistula in infancy and childhood: diagnostic and therapeutic aspects. Thorac Cardiovasc Surg 1997; 45: 287-94.
42. Shubrooks S, Naggar C. Spontaneous near closure of coronary artery fistula. Circulation 1978; 57: 197-9.
43. Kirklin JW, Barratt-Boyes BG. Congenital anomalies of the coronary arteries. In: Kirklin JW, Barratt-Boyes BG, eds. Cardiac surgery. 2nd edition. New York, NY: Churchill-Livingstone, 1993: 945-55.
44. Perry SB, Keane JF, Lock JE. Pediatric Intervention. In: Grossman W, Baim DS, eds. Cardiac catheterization, angiography, and intervention. Philadelphia, PA: Lea & Febiger, 1991: 543-4.
45. Rittenhouse E, Doty D, Ehrenhaft J. Congenital coronary artery-cardiac chamber fistula: review of operative management. Ann Thorac Surg 1975; 20: 468-85.
46. Bennett JM, Maree E. Successful embolization of a coronary arterial fistula. Int J Cardiol 1989; 23: 405-6.
47. Reidy J, Anjos R, Qureshi S, Baker E, Tynan M. Transcatheter embolization in the treatment of coronary artery fistulas. J Am Coll Cardiol 1991; 18: 187-92.
48. Hakim F, Madani A, Goussous Y, Cao QL, Hijazi ZM. Transcatheter closure of a large coronary arteriovenous fistula using the new Amplatzer™ duct occluder. Cathet Cardiovasc Diagn 1998; 45: 155-7.
49. Perry SB, Radtke W, Fellows KE, Keane JF, Lock JE. Coil embolization to occlude aorto-pulmonary collateral vessels and shunts in patients with congenital heart disease. J Am Coll Cardiol 1989; 13: 100-8.
50. Qureshi S, Reidy J, Alwi M, et al. Use of interlocking detachable coils in embolization of coronary arteriovenous fistulas. Am J Cardiol 1996; 78: 110-3.
51. Perry S, Rome J, Keane J, Baim D, Lock J. Transcatheter closure of coronary artery fistulas. J Am Coll Cardiol 1992; 20: 205-9.
52. Lacombe P, Rocha P, Marchand X, et al. High flow coronary fistula closure by percutaneous coil packing. Cathet Cardiovasc Diagn 1993; 28: 342-6.
53. Ragnarsson A, Emanuelsson H. Treatment of a large congenital coronary fistula with coil embolization. Scand Cardiovasc J 1999; 33: 57-9.
54. Sangiorgi G, Castelvecchio S, Inglese L. Successful double percutaneous alcohol and coil embolization of bilateral coronary-to-pulmonary artery fistulas. J Interv Cardiol 2000; 13: 209-14.
55. Sigwart U. Non-surgical myocardial reduction for hypertrophic obstructive cardiomyopathy. Lancet 1995; 346: 211-4.
56. Yakes WF, Pevsner P, Reed M, Donohue HJ, Ghaed N. Serial embolizations of an extremity arteriovenous malformation with alcohol via direct percutaneous puncture. AJR Am J Roentgenol 1986; 146: 1038-40.
57. Yakes WF, Krauth L, Ecklund J, et al. Ethanol endovascular management of brain arteriovenous malformations: initial results. Neurosurgery 1997; 40: 1145-54.
58. Yakes WF, Rossi P, Odink H. How I do it. Arteriovenous malformation management. Cardiovasc Intervent Radiol 1996; 19: 65-71.
59. Kambara A, Pedra C, Esteves C, et al. Transcatheter embolization of congenital coronary arterial fistulas in adults. Cardiol Young 1999; 9: 371-6.
60. Harris WO, Andrews JC, Nickols DA, Holmes DRJ. Percutaneous transcatheter embolization of coronary arteriovenous fistulas. Mayo Clin Proc 1996; 71: 37-42.
61. Thomson L, Webster M, Wilson N. Transcatheter closure of a large coronary artery fistula with the Amplatzer™ duct occluder. Catheter Cardiovasc Interv 1999; 48: 188-90.
62. Welge D, Haude M, Von Birgelen C, et al. Treatment of coronary artery perforation with a new membrane-covered stent. Z Kardiol 1998; 87: 948-53.
63. Von Birgelen C, Haude M, Herrmann J, et al. Early clinical experience with the implantation of a novel synthetic coronary stent graft. Catheter Cardiovasc Interv 1999; 47: 496-503.
64. Di Mario C, Inglese L, Colombo A. Treatment of a coronary aneurysm with a new polytetrafluoethylene-coated stent: a case report. Catheter Cardiovasc Interv 1999; 46: 463-5.
65. Heuser RR, Woodfield S, Lopez A. Obliteration of a coronary artery aneurysm with a PTFE-covered stent: endoluminal graft for coronary disease revisited. Catheter Cardiovasc Interv 1999; 46: 113-6.
66. Thalhammer C, Kirchherr A, Uhlich F, Waigand J, Gross C. Postcatheterization pseudoaneurysms and arteriovenous fistulas: repair with percutaneous implantation of endovascular covered stents. Radiology 2000; 214: 127-31.
67. Balanescu S, Sangiorgi G, Medda M, Chen Y, Castelvecchio S, Inglese L. Successful concomitant treatment of a coronary to pulmonary artery fistula and a left anterior descending artery stenosis using a single covered stent graft: a case report and literature review. J Interv Cardiol, in press.
68. Roongsritong C, Laothavorn P, Sa-nguanwong S. Stent grafting for coronary arteriovenous fistula with adjacent atherosclerotic plaque in a patient with myocardial infarction. J Invasive Cardiol 2000; 12: 283-5.