Images in cardiovascular medicine

Transcatheter closure of a stabilized post-infarction apical muscular septum defect as an alternative to surgical repair

Mario Zanchetta, Eustaquio Onorato, Gianluca Rigatelli, Luigi Pedon, Mario Barbiero*, Marco Zennaro, Giorgio Rigatelli*, Pietro Maiolino

*Department of Cardiovascular Disease, Cittadella General Hospital, Cittadella (PD), *Department of Medical Sciences, Division of Cardiology, Legnago General Hospital, Legnago (VR), Italy*

(Ital Heart J 2002; 3 (10): 620-621)

Received July 9, 2002; revision received August 26, 2002; accepted August 29, 2002.

Address:

Dr. Mario Zanchetta

Dipartimento di Malattie Cardiovascolari ASSL 15 "Alta Padovana" Via Riva dell'Ospedale 35013 Cittadella (PD) E-mail: emodinacit@ulss15.pd.it

Rupture of the interventricular septum accounts for 0.2% of all complications of acute myocardial infarction, frequently occurring within the end of the first weeks[1]. The main risk factors for this complication are advanced age, anterior infarct and female gender. Medical treatment is almost ineffective and the surgical mortality remains high (25-50%), with up to 40% of patients presenting with recurrent shunting. On the other hand, there are no data on the transcatheter closure of a post-infarction myocardial ventricular septal defect (VSD) because the clinical experience is minimal.

An 82-year-old woman was admitted to the intensive care unit with a diagnosis of anterior myocardial infarction. She was medically managed for a completed infarction involving the distal interventricular septum and the apical segments without an impaired left ventricular function. Six days following admission, the patient developed severe hypotension and profound dyspnea requiring intravenous inotropic support, an intra-aortic balloon pump and subsequent intubation. Transthoracic echocardiography revealed the presence of a defect in the apical septum with an estimated diameter, at planimetry, of 16 mm. There was severe left-to-right shunting and the left ventricular ejection fraction was 70%. The cardiothoracic surgeon rejected early surgical repair because of the patient's advanced age, severe hemodynamic instability and renal insufficiency, all of which are associated with an extremely high mortality. It was hence decided to submit the patient to a percutaneous approach if she survived the initial admission. The risks and benefits of the procedure were discussed with the patient and her family and written informed consent was obtained. The patient underwent cardiac catheterization under local anesthesia 24 days after the onset of the myocardial infarction. Right heart evaluation, performed via the right internal jugular vein, revealed a significant oxygen saturation step-up from the right atrium (68.9%) to the right ventricle (88.7%) with a Qp/Qs ratio of 3.4. The left ventriculogram, performed in the left oblique-cranial view with a 4F pigtail catheter introduced via the right femoral artery, showed antero-apical akinesis with a large VSD (Fig. 1a). The coronary angiogram revealed total occlusion of the infarct-related left anterior descending coronary artery with minimal collaterals, and normal circumflex and right coronary arteries. The VSD was crossed using a retrograde arterial approach with a 4F pigtail catheter and a 0.035" × 260 cm angled guide wire (Terumo Corporation, Tokyo, Japan). The end of the wire was then snared using a 10 mm Amplatzer goose-neck (Microvena Corporation, White Bear Lake, MN, USA) introduced through the right internal jugular sheath and forming an arteriovenous wire loop (Fig. 1b). A balloon sizing maneuver was performed using a large occlusion balloon catheter (Medi-Tech, Boston Scientific Corporation, Natick, MA, USA), and the stretched diameter confirmed the 16 mm VSD (Fig. 1c). A 12F Check-Flo performer

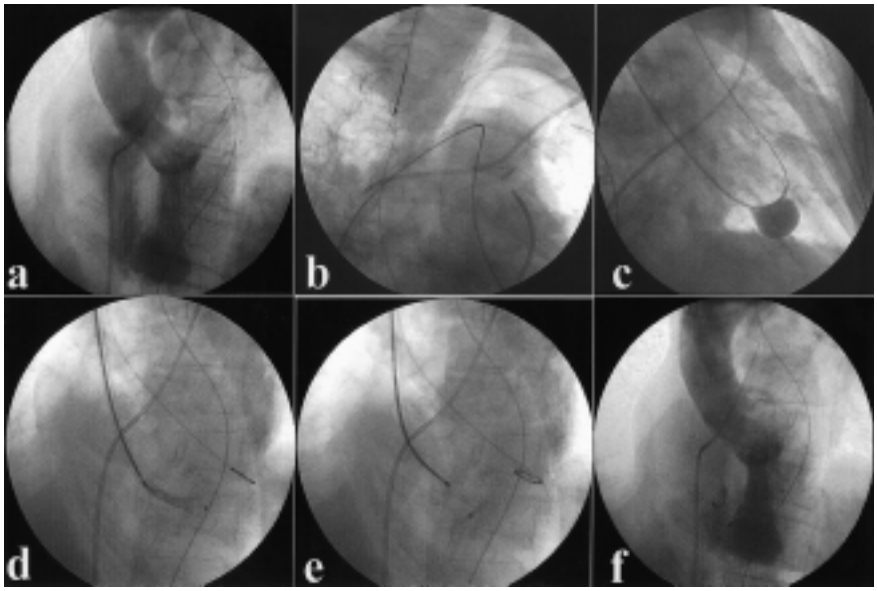

Figure 1. a: *left ventricular angiogram (45° left anterior oblique-35° cranial view) shows the apical muscular ventricular septal defect;* b: *arteriovenous wire loop from the femoral artery through the ventricular septal defect and out through the right internal jugular vein;* c: *large occlusion balloon catheter inflated and pulled to close the ventricular septal defect;* d: *deployment of the left disk in the left ventricle;* e: *deployment of the connecting wire and the right disk after pulling back the device onto the interventricular septum;* f: *repeat left ventricular angiogram confirming adequate positioning of the device and minimal residual shunting through the device.*

introducer Mullins type (William Cook Europe A/S, Bjaeverskov, Denmark) was exchanged for the right internal jugular sheath and advanced over the wire loop, crossing the VSD into the outflow tract of the left ventricle. A 20 mm Amplatzer muscular VSD occluder was implanted under fluoroscopic guidance alone: the left disk was initially extruded and pulled back onto the left side of the interventricular septum (Fig. 1d) and subsequently the right disk was deployed (Fig. 1e). Having ensured adequate placement by means of left ventricular angiography, the device was released.

The patient's hemodynamic picture improved shortly after the procedure. The systemic blood pressure increased from 61/39 to 109/50 mmHg, whereas the pulmonary artery pressure did not change significantly (from 40/9 to 38/12 mmHg). Repeat right heart oximetry showed a fall in the step-up of oxygen saturation with a reduction in the pulmonary artery from 88.7 to 74.4%. The final left ventriculogram documented the adequate positioning of the device in the presence of just a minimal residual shunt (Fig. 1f). At 3 months of follow-up there were no clinical signs of heart failure and transthoracic echocardiography revealed a correct device position without shunting.

The timing of both the surgical and percutaneous interventions is one of the most challenging questions. On one hand, early treatment avoids severe hemodynamic instability, but contributes to the high rate of recurrent shunting or of percutaneous device embolization due to the continued maturation of the myocardial infarction over time. On the other hand, a delayed repair intervention, after the VSD has reached full size, exposes patients to the danger of right ventricular dysfunction and multiorgan failure due to low cardiac output and pulmonary edema. For these reasons, there is a general consensus in the cardiovascular community that the best results are achieved in patients surviving for at least 4 weeks. This may be the time necessary for significant scar formation on the edges of the VSD.

Our case underlines that the patients likely to be the most common candidates for catheter-based VSD closure are those who survive the initial admission with the use of inotropic support and of the intra-aortic balloon pump. This implies a smaller extension of damaged myocardium, a smaller size of the defect and less severe coronary artery disease, suggesting that such patients are self selected.

Reference

1. Crenshaw BS, Granger CB, Birnbaum Y, et al. Risk factors, angiographic patterns, and outcomes in patients with ventricular septal defect complicating acute myocardial infarction. GUSTO-I (Global Utilization of Streptokinase and TPA for Occluded Coronary Arteries) Trial Investigators. Circulation 2000; 101: 27-32.

Italian Heart Journal

Official Journal
of the Italian Federation
of Cardiology

Italian Federation of Cardiology
Division of Cardiology
IRCCS Policlinico San Matteo
Piazzale Golgi, 2 - 27100 Pavia, Italy
tel. +39-0382.525838, fax +39-0382.525834

Italian Heart Journal is the Official Journal of the Italian Federation of Cardiology, published monthly by **CEPI - AIM Group**, via N. Tartaglia 3, 00197 Rome, Italy, tel. +39-06.8077011-8082101, fax +39-06.8072458, e-mail: p.luciolli@cepi.it

On-line
Abstracts and full text of articles are available at the website www.italheartj.org

Annual subscription rates
Annual subscription rates cover the period from January 1 to December 31 and include two monthly issues (Italian Heart Journal and Italian Heart Journal Supplement) and two Abstracts Supplements. Prepayment is required. To enter a subscription, please send or transmit via fax the form here enclosed duly filled in together with the copy of your payment. Single copies or back issues may be obtained by sending request to the following e-mail address: m.federici@cepi.it

✂ .....

One year subscription rate: Italy € 51,65 - Rest of the world US$ 100, single copy € 4,39 or US$ 8 - back issues € 8,78 or US$ 15
□ Subscription to ***Italian Heart Journal*** 2003
□ Request for issue(s) ...../2002
□ Request for back issue(s) ...../year .....

Methods of payment:
□ cheque no. ..... (headed to CEPI Srl)
□ bank draft on account headed to CEPI Srl no. 12876/24, CIN K, ABI code 03069, CAB 05065, of Banca Intesa-Bci - Agenzia 490 - via Po 166, 00198 Rome, Italy, Europee (IBAN): IT39 K030 6905 0650 0000 1287 624

Send journal to:
Name .....
Address .....
City ..... ZIP code ..... Country .....

Data required for the invoice:
Name .....
Address .....
City ..... ZIP code ..... Country .....
VAT registration number .....
Date ..... Signature .....

EU members please specify your VAT registration number
"The subscriber gives his express authorization according to the law December 31st, 1996, no. 675. The data collected by this order form, whose discretion is guaranteed, shall be recorded in the CEPI Srl data bank and shall be used to send the requested publications". According to article no. 13 of the law December 31st, 1996, no. 675, the above-mentioned information shall be destroyed upon the subscriber's request.

✂ .....

Managing Editor
Marinella Buongiorno

Registered as a journal at the Tribunal of Rome no. 623/99 December 24, 1999

Published in October 31, 2002
by Arti Grafiche Tris, via A. Dulceri 126-128, 00176 Rome, Italy
tel. +39-06.2754686, fax +39-06.2754666