Case reports

Infective endocarditis due to *Capnocytophaga canimorsus*

Alessandro Frigiola, Toni Badia, Roberto Lovato*, Alberto Cogo*, Maria Pia Fugazzaro*, Roberto Lovisetto**, Marisa Di Donato***

*Cardiovascular Center "Malan", Istituto Policlinico San Donato, San Donato Milanese (MI), *Division of Medicine, Casa di Cura Villa Berica, Vicenza, **Division of Microbiology and Virology, San Bortolo Hospital, Vicenza, ***Department of Critical Care Medicine and Surgery, University of Florence, Florence, Italy*

Key words:
Endocarditis; Mitral regurgitation.

We report the case of a 41-year-old woman with severe mitral regurgitation due to infective endocarditis caused by a rare zoonotic microorganism (*Capnocytophaga canimorsus*).

She had had a rheumatic mitral endocarditis successfully treated with antibiotics when she was 13 years old. She arrived to our attention for a fever of unknown origin. She had been bitten by her dog and medicated the wound herself. About 2 weeks later she developed a fever with values up to 39.5°C.

Blood cultures were initially negative but in view of her particular history (dog bite), the samples were sent to a specialized center where a *Capnocytophaga canimorsus* (a commensal bacterium contained in the saliva of dogs and cats) infection sensitive to ceftriaxone was detected. The antibiotic therapy was consequently modified and the patient's fever resolved.

At echocardiography a mild mitral stenosis with severe regurgitation (3-4+/4+) was detected.

We planned surgical mitral repair but the operative findings clearly showed the need for mitral replacement and a 29 mm size bileaflet mechanical prosthesis was implanted. The postoperative course was regular and the patient was discharged on the fifth day.

We highlight the importance of a careful history and correct work-up for the diagnosis and treatment of false negative blood culture endocarditis.

(Ital Heart J 2003; 4 (10): 725-727)

Received March 24, 2003; revision received June 12, 2003; accepted June 19, 2003.

Address:

Dr. Alessandro Frigiola

Centro Cardiovascolare "Malan"
Istituto Policlinico San Donato
Via Morandi, 30
20097 San Donato Milanese (MI)
E-mail: tonibi@inwind.it

Introduction

Infective endocarditis caused by a zoonotic microorganism is a rare clinical condition. *Capnocytophaga canimorsus* is a commensal bacterium living in the saliva of dogs and cats, which may be transmitted to humans by a bite, scratch or by mere exposure to the animals.

Infection may occur in previously healthy adults but immune-compromised, asplenic or alcoholic patients are particularly at risk[1-4]. It has been associated with a variety of conditions including septicemia, meningitis and septic arthritis[5]. Very few cases of endocarditis have been described.

Case report

A 41-year-old woman came to our attention for a fever of unknown origin. Her history included: heavy smoking (25 cigarettes/day) for many years and rheumatic fever and mitral endocarditis successfully treated with antibiotics when she was 13 years old; since then, the patient adopted an antibiotic prophylaxis and she was free from cardiovascular symptoms. She annually submitted herself to a follow-up control visit including echocardiography that revealed mitral anterior and posterior leaflet prolapse with mild mitral regurgitation.

No other cardiovascular risk factors or relevant pathology were present; in particular, there was no history of any underlying disease potentially leading to immunosuppression and no history of alcohol abuse.

She reported that she was recently bitten on her left thumb by the family dog (a Rotwailer) and that she had medicated the wound herself.

Two weeks later, the patient presented with mild fever (38°C) which responded to paracetamol, followed by 4-5 days of intermittent fever (maximum temperature of 39.5°C) associated with asthenia. For this reason she was hospitalized. At her arrival, the patient was eupnoic, with tachycardia; physical examination showed a 3/6 holosystolic murmur at the apex radiating to the armpit; the general neurological examination was normal.

Echocardiography revealed the presence of thickened and prolapsed mitral edges with filaments on both sides, in particular on the posterior edge which appeared mobile on the atrial side; at color Doppler investigation, evidence of mild stenosis and severe mitral insufficiency originating from the posterior mitral edge (grade 3-4+/4+) was detected.

Hematological analysis revealed increased inflammatory indexes: a high erythrocyte sedimentation rate (111 mm/hour), neutrophil leukocytosis (16 300 white blood cells, 85% neutrophils), and mild normocytic anemia (hemoglobin 11.7 g/l).

An empiric antibiotic therapy – mezlocillin 3 g × 4 i.v. and gentamicin 80 mg × 3 i.v. – was started while waiting for the results of the blood culture. After 8 days during which the patient had no fever, her temperature started to increase reaching a peak of 38.4°C. For this reason we decided to substitute mezlocillin with piperacillin + tazobactam but the fever persisted.

The blood cultures were negative but because of patient's peculiar anamnesis (dog bite), we decided to send the samples to a specialized center (Pasteur Institute, Paris, France) where a *C. canimorsus* infection sensitive to ceftriaxone (MIC 0.125 μg/ml) was detected. The antibiotic therapy was consequently modified adopting only ceftriaxone (3 g × 2 i.v. on the the first day followed by 2 g i.v. once daily) and the fever resolved.

Twenty days later severe mitral insufficiency, presumably related to the episode of endocarditis, developed (4+/4+) with a progressive worsening in the patient's clinical conditions. The only operative option was mitral valve surgery and mitral repair was planned. However, operative inspection of the valve clearly showed the need of replacement. As shown in figure 1 a thickened and severely compromised mitral valve leaflet was in fact detected. A 29 mm bileaflet mechanical prosthesis was therefore implanted.

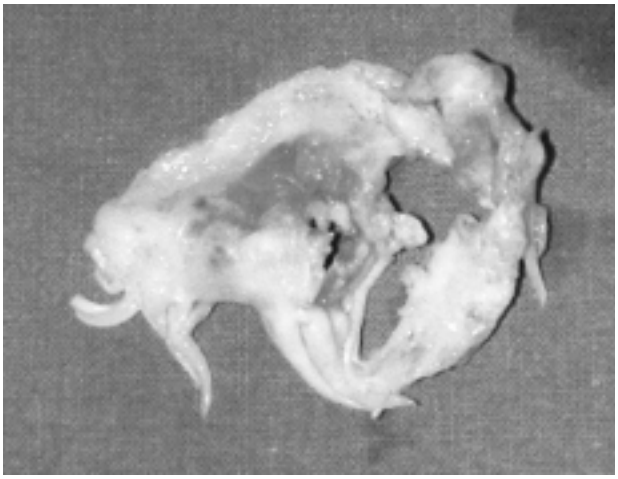

Figure 1. *Excised mitral valve.*

Unfortunately, the resected valve was not sent for histological or culture examination. The postoperative course was regular and the patient was discharged on the fifth day.

Discussion

The first report of a previously unidentified gram-negative bacillus causing septicemia and meningitis appeared in 1976[6]. In view of its characteristics, the Center of Disease Control (Atlanta, GA, USA) gave it the name of dysgonic fermenter-2 (DF-2). In 1989 the official name *Capnocytophaga canimorsus* (Latin for "dog bite") was proposed.

Capnocytophaga species are long, thin, gram-negative rods that are facultative anaerobes, but they grow best in an atmosphere enriched with carbon dioxide, from which the name of the genus is derived.

Various *Capnocytophaga* species colonize the human oral cavity, including *C. gingivalis*, *C. ochraceus* and *C. sputigena* of the DF-1 group of bacilli; species that colonize the canine oral cavity include *C. canimorsus* of the DF-2 group and the DF-2-like species such as *C. cynodegmi*[7].

C. canimorsus is positive for catalase and this characteristic distinguishes it from DF-1 species which are typically negative for this enzyme. This bacillus, which is part of the normal oral flora of dogs, cats and other animals, is known to cause septic shock in immunocompromised patients.

Infections occur predominantly in adults, more often in men (about two thirds of cases) than in woman, and most patients have been either bitten by or otherwise exposed to a dog. In many cases, the exposure is trivial.

In American series, animal bites were the presenting complaint in about 1% of all referrals to emergency rooms[1]; although patients with severe bite injuries usually present early, apparently trivial injuries may manifest later due to an insidiously developing local or systemic infection.

C. canimorsus sepsis has been associated with asplenia (in 38% of cases), a history of alcohol abuse (in 30%)[2], cirrhosis[3] and usually develops in immunocompromised patients, particularly those with granulocytopenia[4] or blood tumor[8]. Many cases have been reported in which there was no apparent predisposing factor[9].

In both normal and asplenic persons, shock, renal failure, the acute respiratory distress syndrome and peripheral gangrene[10] are common complications of bacteremia, and disseminated intravascular coagulation occurs in more than one third of infected patients[11]. The mortality due to bacteremia is approximately 30%.

Pers et al.[9] reviewed 39 cases of *C. canimorsus* infection in Denmark: 22 cases were associated with dog bites, and 4 with episodes in which dogs had licked preexisting lesions. Thirteen patients had previously been

in good health. Many of the patients presented with fever and gastrointestinal symptoms such as vomiting, diarrhea, and abdominal pain. Disseminated intravascular coagulation developed in 14 of the 39 patients, and 12 patients had fatal fulminant septicemia. The case-fatality rate ranged from 25 to 30%.

Myocardial infarction in asplenic patients with normal coronary arteries has also been described[12,13]. Endocarditis in the aortic[14], mitral[15] and tricuspid[16] positions has also been reported.

This case highlights the potential of *C. canimorsus* to give rise to endocarditis. Blood cultures may be negative, thus delaying the diagnosis and appropriate treatment. Our case confirms that no animal bite should be regarded as innocuous. The true cause of our patient's illness became clear only after *Capnocytophaga* had been isolated from blood cultures, highlighting the importance of a careful history and work-up in the formulation of a correct diagnosis and treatment of false negative blood culture endocarditis.

The present case reasserts the need for rigorous wound toilet and appropriate antibiotic prophylaxis in all cases of an animal bite regardless of its extent.

References

1. Wiggins ME, Akelman E, Weiss AP. The management of dog bites and dog bite infections to the hand. Orthopedics 1994; 17: 617-23.
2. Parsonnet J, Versalovic J. A 42-year-old asplenic man with gram-negative sepsis. N Engl J Med 1999, 340: 1819-26.
3. Roblot P, Bazillou M, Grollier G, Becq-Giraudon B, Fauchere JL. Septicaemia due to Capnocytophaga canimorsus after a dog bite in a cirrhotic patient. Eur J Clin Microbiol Infect Dis 1993; 12: 302-3.
4. Parenti DM, Snydman DR. Capnocytophaga species: infections in nonimmunocompromised and immunocompromised hosts. J Infect Dis 1985; 151: 140-7.
5. Hovenga S, Tulleken JE, Moller LV, Jackson SA, Van Den Werf TS, Zijlstra JG. Dog-bite induced sepsis: a report of four cases. Intensive Care Med 1997; 23: 1179-80.
6. Bobo RA, Newton EJ. A previously undescribed Gram-negative bacillus causing septicemia and meningitis. Am J Clin Pathol 1976; 65: 564-9.
7. Brenner DJ, Hollis DG, Fanning GR, Weaver RE. Capnocytophaga canimorsus sp nov (formerly CDC group DF-2), a cause of septicemia following dog bite, and C cynodegmi sp nov, a cause of localized wound infection following dog bite. J Clin Microbiol 1989; 27: 231-5.
8. Bilgrami S, Bergstrom SK, Peterson DE, et al. Capnocytophaga bacteremia in a patient with Hodgkin's disease following bone marrow transplantation: case report and review. Clin Infect Dis 1992; 14: 1045-9.
9. Pers C, Gahrn-Hansen B, Frederiksen W. Capnocytophaga canimorsus septicemia in Denmark, 1982-1995: review of 39 cases. Clin Infect Dis 1996; 23: 71-5.
10. Mellor DJ, Bhandari S, Kerr K, Bodenham AR. Man's best friend: life threatening sepsis after minor dog bite. BMJ 1997; 314: 129-30.
11. Krol-van Straaten MJ, Landheer JE, de Maat CE. Capnocytophaga canimorsus (formerly DF-2) infections: review of the literature. Neth J Med 1990; 36: 304-9.
12. Scharf C, Widmer U. Myocardial infarction after dog bite. Circulation 2000, 102: 713-4.
13. Mitchell I, McNeillis N, Bowden FJ, Nikolic G. Electrocardiographic myocardial infarction pattern in overwhelming post-splenectomy sepsis due to Capnocytophaga canimorsus. Intern Med J 2002; 32: 415-8.
14. Decoster H, Snoeck J, Pattyn S. Capnocytophaga canimorsus endocarditis. Eur Heart J 1992; 13: 140-2.
15. Butler T, Weaver RE, Ramani TK, et al. Unidentified gram-negative rod infection: a new disease of man. Ann Intern Med 1977; 86: 1-5.
16. Andersen HK, Pedersen M. Infective endocarditis with involvement of the tricuspid valve due to Capnocytophaga canimorsus. Eur J Clin Microbiol Infect Dis 1992; 11: 831-2.