Usefulness of multiplane transesophageal echocardiography in the recognition of artifacts and normal anatomical variants that may mimic left atrial thrombi in patients with atrial fibrillation

Anna Maltagliati, Mauro Pepi, Gloria Tamborini, Manuela Muratori, Fabrizio Celeste, Elisabetta Doria, Claudia Galli

Centro Cardiologico Monzino, IRCCS, Milan, Italy

Key words:
Atrial fibrillation; Transesophageal echocardiography.

Background. **Transesophageal echocardiography (TEE) is the method of choice for the evaluation of the left atrium and of left atrial appendage (LAA) thrombosis. However, the anatomy of the left appendage is complex and reverberations from anatomical structures may create images and ghosting which mimic left atrial thrombosis. The purpose of this study was to investigate whether a systematic approach through TEE may facilitate the recognition of LAA anatomical variants and artifacts.**

Methods. **One hundred and sixty-four consecutive patients scheduled for cardioversion of atrial fibrillation (study population) and 30 patients (control group) undergoing mitral valve surgery were submitted to TEE using a multiplane probe in order to obtain a systematic evaluation of the LAA. The number of LAA lobes and the presence of thrombi and artifacts were evaluated.**

Results. **The majority of the study patients had a bilobed (53.1%) or single-lobed (34.1%) LAA. Thrombi were identified in 6%. Artifacts were found in 38 cases (23.2%) and their position was localized precisely at a distance from the transducer which was twice that from the partition-bend between the left upper pulmonary vein and left appendage, suggesting a reverberation. No differences in echocardiographic parameters were found in patients with (group 1) or without (group 2) artifacts. Cardioversion was successful in a similar percentage of cases in the two groups (group 1 68%, group 2 76%) without complications. In controls, the percentages of a single- (33%) and bilobed (40%) left appendage were similar to those found in the study population. Artifacts were identified in 11 controls (37%); no thrombi were detected during surgical left appendage inspection in these cases.**

Conclusions. **A systematic approach with multiplane TEE facilitates the evaluation of the LAA anatomy and the recognition of artifacts, thus reducing the likelihood of false positive or negative diagnoses of left appendage thrombi.**

(Ital Heart J 2003; 4 (11): 797-802)

Received May 22, 2003; revision received September 18, 2003; accepted September 30, 2003.

Address:

Dr.ssa Anna Maltagliati

Centro Cardiologico Monzino, IRCCS
Via Parea, 4
20138 Milano
E-mail:
anna.maltagliati@cardiologicomonzino.it

Transesophageal echocardiography (TEE) provides a unique diagnostic window for the evaluation of the left atrium and left atrial appendage (LAA) and allows thrombi in these structures to be detected with a high degree of accuracy[1-5]. Its use has therefore been proposed as a guide to allow cardioversion to be performed earlier and safer[6]. However, the anatomy and function of the LAA are complex due to the variability in the number of lobes (single-lobed, bilobed or multilobed), in its size and shape and in the thickness and length of the pectinate muscles (large or small pectinate muscles)[4,7-9]. For all these reasons the TEE examination should be detailed and even though improved imaging techniques (in particular the use of multiplane TEE) have allowed to visualize completely the LAA, the interpretation of TEE findings and the recognition of thrombi may be difficult. Moreover, reverberations from anatomical structures may further disturb the evaluation of intra-auricular masses and may create images and ghosting which mimic left atrial (LA) thrombosis. Since it is imperative that atrial thrombi be accurately identified (to reduce the likelihood of embolic events) and it is also very important to minimize false positive results (to avoid cases with a mistakenly posed contraindication to cardioversion) TEE should be as detailed and accurate as possible.

We performed a prospective study of consecutive patients undergoing multiplane TEE before cardioversion a) to determine the prevalence of single- or multilobed LAA; b) to calculate the prevalence

of artifacts or other images that may mimic thrombi and define the technical criteria to differentiate these findings; c) to evaluate the TEE correlates of the clinical risk of thromboembolism after cardioversion.

Methods

Patients. We studied 164 consecutive patients (101 males, 63 females, mean age 63 ± 11 years, study population) undergoing multiplane TEE before cardioversion of atrial flutter (33 cases) or fibrillation (131 cases) lasting > 2 days (mean 62 ± 54 days, range 2-360 days) and 30 patients (19 males, 11 females, mean age 54 ± 14 years, control group) submitted to cardiac surgery because of mitral valve disease. Twenty-one patients of the control group had mitral valve prolapse and 9 had mitral valve stenosis; all but 2 were in sinus rhythm. In these patients, direct surgical inspection of the LA and LAA cavities was performed, allowing us to differentiate ghosting from thrombi.

Study protocol. After written informed consent, all patients underwent transthoracic echocardiography and TEE examinations. If TEE excluded the presence of LA or LAA thrombi, the patients of the study population were submitted to cardioversion. A 4-week follow-up was performed and complications were annotated.

Transthoracic echocardiography. All patients underwent chest X-ray and transthoracic echocardiography (Hewlett-Packard Sonos 5500, model 21364A, Andover, MA, USA or Acuson Sequoia C256, Mountain View, CA, USA). Two-dimensional measurements were obtained according to the standards of the American Society of Echocardiography[10]. Left ventricular volumes and ejection fraction were measured by the area-length method[10].

Multiplane transesophageal echocardiography. Multiplane TEE was performed within 24 hours of the scheduled cardioversion. TEE was performed after having administered pharyngeal anesthesia using xylocaine spray. The majority of patients were given intravenous sedation with midazolam (2 to 5 mg i.v.); the probe was then inserted into the esophagus and connected to the ultrasound unit (Hewlett-Packard 5500); investigations were carried out with the patients in the supine left lateral position.

The probe was initially advanced to a depth of 25 to 35 cm and then manipulated to optimize imaging of the atria and of the LAA. The LA and LAA images were obtained in different planes from 0 to 180°. Imaging of the left atrium and LAA was begun in the horizontal plane (0°); then the transducer was rotated progressively to 60 and 90°; at the same degrees images were also evaluated after slight and more pronounced counterclockwise (toward the patient's left) rotation of the probe; finally electronic rotation of the transducer to 110 and 130° was coupled with more pronounced counterclockwise rotation of the probe. Electronic rotation of the transducer to 180° was then performed. All images were recorded zooming the LAA and optimizing the gain settings and post-processing to minimize gray-noise artifacts.

In accordance with previously described methods[11-15] we analyzed: the LAA maximum area in the short- and long-axis views (measured by tracing a line starting from the top of the limbus of the left upper pulmonary vein along the entire endocardial border, immediately preceding the initiation of the QRS complex); the number of LAA lobes (a lobe was defined as a visible outpouching from the main tubular body of the LAA, usually demarcated by an external crease); the LAA peak filling and peak emptying velocities, obtained by placing the pulsed Doppler sample volume into the outlet of the appendage cavity (average of 5 cardiac cycles); the presence or absence of LA or LAA thrombosis, described as echo-dense masses, mobile or immobile, connected to the LA or LAA wall; the presence of spontaneous echocontrast, graded as 0 (none, absence of echogenicity), 1+ (mild, minimal echogenicity located in the LAA or sparsely distributed in the main cavity of the left atrium, which may be detectable only transiently during the cardiac cycle and which is imperceptible at the operating gain settings for two-dimensional echocardiographic analysis), 2+ (mild to moderate, a more dense swirling pattern than 1+ but with a similar distribution, detectable without increased gain settings), 3+ (moderate, a dense swirling pattern in the LAA, generally associated with a somewhat lesser intensity in the main cavity; it may fluctuate in intensity but is constantly detectable throughout the cardiac cycle), 4+ (severe, intense echo-density and very slow swirling patterns in the LAA, usually with a similar density in the main cavity).

Artifact images were considered when a location and echogenicity suggestive of reverberations were obtained at different TEE rotational angles; in particular, artifacts were supposed to be found in the LAA twice as far from the transducer as an anatomical interface (specifically, the partition-bend between the left upper pulmonary vein and the LAA). Therefore the distances of each thrombus-like image from the transducer and from other anatomical interfaces were measured; the echogenicity and other anatomical characteristics of each intra-auricular image were also evaluated.

All images were recorded on videotape and re-evaluated in the echocardiographic laboratory by two independent observers.

Statistical analysis. All data are expressed as mean ± SD. The data of the different groups were compared using the Student's unpaired t-test. We compared categorical variables using the χ^2 test (with continuity correction for small numbers). A p value < 0.05 was considered as statistically significant.

Results

The clinical and echocardiographic features of the entire study group are shown in table I. The majority of our patients had hypertension, valve disease or lone atrial fibrillation. All but 3 patients were anticoagulated; the anticoagulation regimens varied widely even though the majority of our study population (120 patients) was treated with warfarin (Table I).

The TEE findings of the study population and controls are shown in table II. The majority of patients had a bilobed (53.1%) or a single-lobed LAA (34.1%) while three- or multilobed appendages were found in a minority of cases (10.4 and 2.4%, respectively). The percentage of single- (33%) and bilobed LAA (40%) in the control group was similar to that detected in the study population. The proposed systematic TEE approach allowed us to correctly identify the number of lobes in views varying from 60 to 145° after slight or pronounced counterclockwise rotation of the probe (Fig. 1).

Thrombi were identified in 10 patients of the study population (6%) while they were not detected in any patient of the control group. Eight of them were in the LAA and 2 in the LA cavity. Fourteen patients (8.6%) had grade 4 spontaneous echocontrast and 5 of them severe spontaneous echocontrast. The latter was considered as a pre-thrombotic state. Figure 2 shows an example of the usefulness of this TEE systematic approach: a small thrombus was identified in one of the two lobes of the LAA thanks to a correct probe manipulation. Artifacts were found in 38 patients (23.2%) and in 11 (37%) controls. Their position was localized precisely at a distance from the transducer (mean 44 ± 8.1 mm) which was twice that from the partition-bend between the left upper pulmonary vein and LAA (mean 22.4 ± 4.8 mm), thus confirming the hypothesis of a reverberation of this anatomical structure (Fig. 3). Moreover, at surgical inspection in the 30 control cases undergoing mitral valve surgery, the LA and LAA cavities were found to be free from thrombotic material. A high correlation between the distance of the artifacts and the distance of the partition-bend from the transducer was demonstrated ($y = 1.97x$; $r^2 = 0.9$).

On the basis of the presence (group 1) or absence (group 2) of artifacts, patients were divided into two groups. No differences in clinical or echocardiographic parameters were found between these two groups (Table III). Group 1 patients had a slightly larger LAA in comparison with group 2 patients, but this difference was not statistically significant.

One hundred and forty-five patients were scheduled for cardioversion, while in 19 cardioversion was postponed due to the presence of LAA or LA thrombi (group 1: 5 cases; group 2: 5 cases), severe pre-thrombotic LAA spontaneous echocontrast (group 1: 1 case; group 2: 4 cases), prosthetic valve dysfunction (mitral paraprosthetic leak, 1 case; mitral prosthetic thrombus, 1 case) or extracardiac causes (2 patients: hepatocellular necrosis, 1 case; the patient denied consent, 1 case). Cardioversion was successful in 26 out of 31 patients (68%) in group 1 without any major complication, and in 97 out of 114 patients (76%) in group 2 (in 1 case transient hemianopsia occurred 20 hours after the procedure).

Table I. Clinical and echocardiographic data of the study population and of the control group.

	Study population	Control group
No. patients	164	30
Sex (M/F)	101/63	19/11
Age (years)	63 ± 11	54 ± 14
Range	30-88	34-73
Pathology		
Coronary artery disease	26 (15.8%)	
Hypertension	51 (31%)	
Valvular disease	29 (17.7%)	30 (100%)
Prosthetic valve	26 (15.8%)	
Lone atrial fibrillation	26 (15.8%)	
Thyroid disease	4 (2.4%)	
WPW syndrome	1 (0.6%)	
Sick sinus syndrome	1 (0.6%)	
Atrial fibrillation	131 (80%)	2 (6.6%)
Atrial flutter	33 (20%)	
Anticoagulant therapy		
Intravenous heparin	25	
Subcutaneous heparin	13	
Warfarin	120	
Antiplatelet agents	3	
Left atrial size (mm)	45.5 ± 7	47.2 ± 7
LVEF (%)	54.1 ± 10	56.5 ± 9

Values are expressed as mean ± SD or number (%) of patients. LVEF = left ventricular ejection fraction; WPW = Wolff-Parkinson-White.

Table II. Transesophageal findings in the study population and in the control group.

	Study population	Control group
No. LAA lobes		
Single lobe	56 (34.1%)	10 (33%)
Two lobes	87 (53.1%)	12 (40%)
Three lobes	17 (10.4%)	5 (16.7%)
Four or more lobes	4 (2.4%)	3 (10%)
No. cases with thrombi	10 (6%)	0
LA thrombus	2 (20%)	
LAA thrombus	8 (80%)	
No. cases with LAA artifacts	38 (23.2%)	11 (37%)
Spontaneous echocontrast		
Grade 0	61 (37%)	25 (83%)
Grade 1	39 (23.7%)	3 (10%)
Grade 2	28 (17.2%)	1 (3.5%)
Grade 3	22 (13.5%)	1 (3.5%)
Grade 4	14 (8.6%)	0

Values are expressed as number (%) of patients. LA = left atrial; LAA = left atrial appendage.

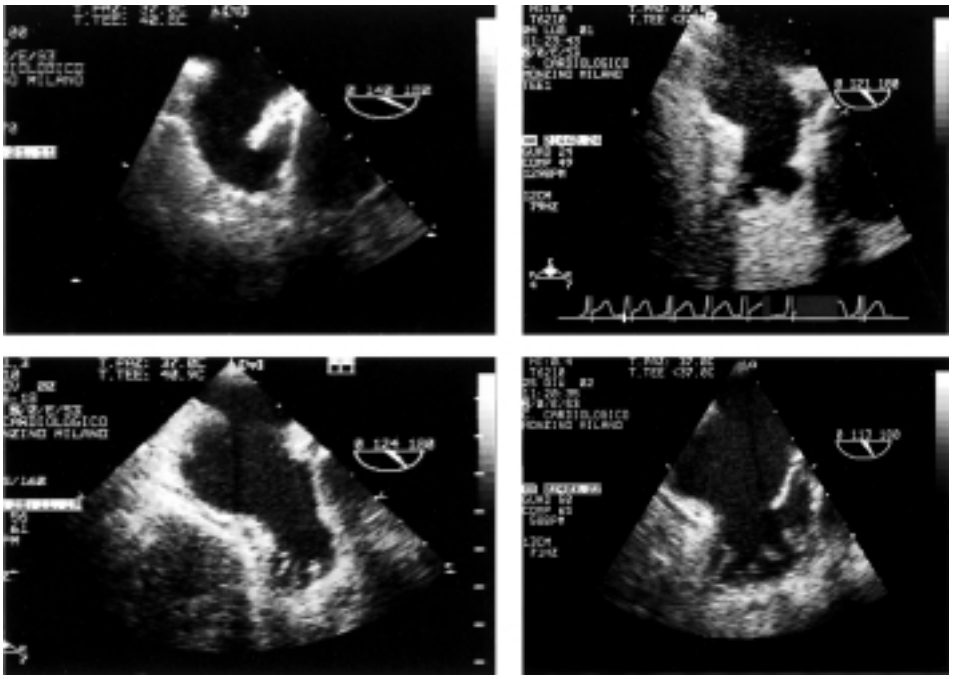

Figure 1. *Four transesophageal examples of anatomical variants of the left atrial appendage obtained in longitudinal planes (over 110°).* Upper left panel: *single-lobed appendage;* upper right panel: *bilobed appendage;* lower panels: *multilobed appendages.*

Figure 2. *Left atrial appendage thrombosis.* Left panel: *at 75° the appendage appears as single-lobed and there is no evidence of any mass within its cavity.* Right panel: *with a rotation of the probe to 134°, the appendage appears as bilobed, and in one of the two lobes a thrombus* (arrow) *is clearly visible.*

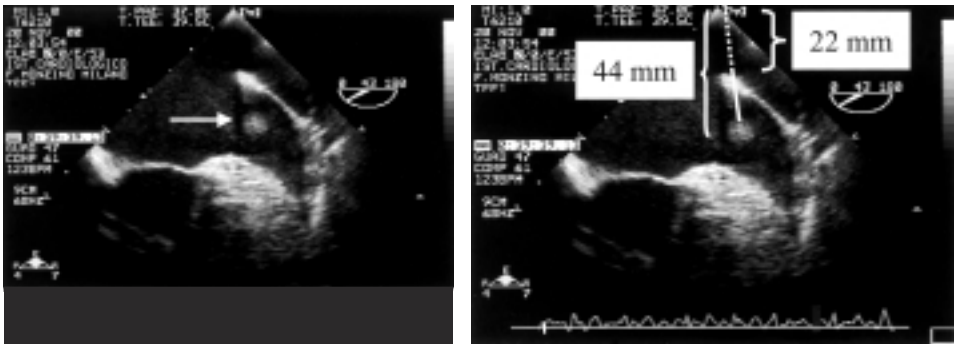

Figure 3. *Left atrial appendage artifact.* Left panel: *the* arrow *indicates an artifact inside the left atrial appendage.* Right panel *(same image as in the left panel): measurements of the distances of the artifact and of the bend between the left atrial appendage and left pulmonary vein from the transducer are shown. The artifact is exactly at twice the distance from the transducer as from the anatomical interface (44 and 22 mm, respectively).*

Table III. Clinical, transthoracic and transesophageal echocardiographic data of the patients with (group 1) and without (group 2) artifact.

	Group 1	Group 2
No. patients	38	126
Age (years)	64 ± 11	63 ± 11
Sex (M/F)	22/16	78/48
LA diameter (mm)	45 ± 8	45 ± 7
LA area (cm^2)	27 ± 5	27 ± 15
LAA area short axis (cm^2)	6.9 ± 2.2	6.2 ± 2.5
LAA area long axis (cm^2)	5.4 ± 2	4.5 ± 1.9
LAA inflow velocity (cm/s)	47.9 ± 20.4	54.3 ± 21.8
LAA outflow velocity (cm/s)	37 ± 17.1	46.2 ± 21.1
LAA outflow velocity ≤ 20 cm/s	11 (29%)	27 (21%)
LVEF (%)	56 ± 11	53 ± 10
Cardioversion		
Scheduled	31 (81%)	114 (90%)
Successful	26 (68%)	97 (76%)
Major embolic events	0	0
Minor embolic events	0	1 (1.03%)

Values are expressed as mean ± SD or number (%) of patients. LA = left atrial; LAA = left atrial appendage; LVEF = left ventricular ejection fraction.

Discussion

Our study demonstrates that a systematic approach using multiplane TEE facilitates the recognition of the LAA anatomical variants and of LAA artifacts, thus reducing the likelihood of false positive and false negative diagnoses of LA thrombosis.

The evaluation of the complex anatomy of the LAA is very important in patients undergoing cardioversion for atrial fibrillation or atrial flutter. Veinot et al.[7] demonstrated in 500 normal autopsy hearts that a majority of cases had a bilobed LAA (54%), 23% and 20% had three and one lobes, respectively, and a minority (3%) had more than three lobes. Our TEE study confirms these findings and percentages in a consecutive series of patients with different pathologies: 53.1% had two LAA lobes, 34.1% one lobe, 10.4% three lobes, and 2.4% four or more lobes. This complex and extremely variable configuration emphasizes the need of routine meticulous echocardiographic scanning of the appendage in multiple planes. Chan et al.[11] and Orsinelli and Pearson[16] described a systematic multiplane TEE approach for the complete visualization of the LAA in 25 cases and in one representative case respectively; we employed a similar method (rotation of the transducer from 0 to 180° coupled with counterclockwise rotation of the probe at 60-90° and 110-130°) in a large series of cases confirming the superiority of multiplane TEE over mono- or biplane TEE in the evaluation of complex anatomical structures[4,5,11]. This method is easy, rapid and facilitates a comprehensive standardized analysis of the LAA morphology. Moreover, the use of these imaging planes may improve the accuracy in detecting LA thrombi since LAA trabeculations, bifurcations and outpouchings could be better evaluated[17,18].

In 23.2% of cases we found images in the LAA which were interpreted as artifacts. This interpretation was based on the assumption that a reverberation is supposed to be found twice as far from the transducer as from an anatomical structure; all artifacts were in fact exactly at twice the distance from the transducer as from the membranous bend between the left upper pulmonary vein and the LAA. Their position and echogenicity were markedly different from those of LAA thrombi; all thrombi found in the LAA (10 cases) were in fact confined within the cavity with an attachment and had a uniform consistency and a different texture to that of the LA wall. None of the artifacts had an attachment to the LAA wall and their consistency was not uniform. Reverberations in echocardiography are very common[19] and during TEE they are frequently seen in the ascending aorta constituting a difficult differential diagnosis of intimal flaps; as described by Appelbe et al.[20] and confirmed by other authors[21], a dilated ascending aorta creates the conditions for reverberations of the atrial-aortic interface within the aortic cavity. Even though we found no direct evidence of our hypothesis in the study population, no thrombi were found at surgical inspection in the patients of the control group who had artifacts. Moreover, no embolic events occurred after cardioversion in the 38 cases with artifacts of the study population. We did not find significant differences between patients with and without artifacts regarding the LAA dimensions, even though those with these reverberations had a slightly larger LAA. The occurrence of artifacts in only one fourth of cases may be due to the position and acoustic properties of the membranous bend. A parallel position of this bend in the acoustic field and a low acoustic reflectivity may in fact reduce the likelihood of this phenomenon.

In patients with atrial fibrillation lasting > 48 hours and not receiving oral anticoagulants the incidence of LA thrombosis is approximately 15%[22]; in our series of patients receiving various regimens of anticoagulants we found a thrombus incidence of 6%, a percentage very similar to other previous studies[1,23-26]. Spontaneous echocontrast inside the LA and LAA cavities was very frequently detected in the study population; however, severe spontaneous echocontrast (grade 3 and 4) was found in approximately 20% of cases, a percentage very similar to that observed in the SPAF III trial[27]. Spontaneous echocontrast was not considered as a contraindication to cardioversion, and in accordance with this approach we did not observe any cardioembolic events. However, in 5 cases the spontaneous echocontrast was so dense (the arbitrary term "prethrombotic state" was used) that cardioversion was postponed.

In conclusion, a systematic approach with multiplane TEE facilitates the evaluation of the complex

anatomy of the LAA and the recognition of artifacts, thus reducing the likelihood of false positive and false negative diagnoses of LAA thrombi.

References

1. Manning WJ, Weintraub RM, Waksmonski CA, et al. Accuracy of transesophageal echocardiography for identifying left atrial thrombi. A prospective, intraoperative study. Ann Intern Med 1995; 123: 817-22.
2. Agmon Y, Khandheria BK, Gentile F, Seward JB. Echocardiographic assessment of the left atrial appendage. J Am Coll Cardiol 1999; 34: 1867-77.
3. Al Saady NM, Obel OA, Camm AJ. Left atrial appendage: structure, function and role in thromboembolism. Heart 1999; 82: 547-55.
4. Manning WJ, Silverman DI. Atrial anatomy and function postcardioversion: insights from transthoracic and transesophageal echocardiography. Prog Cardiovasc Dis 1996; 39: 33-46.
5. Silverman DI, Manning WJ. Role of echocardiography in patients undergoing elective cardioversion of atrial fibrillation. Circulation 1998; 98: 479-86.
6. Klein AL, Grimm RA, Murray RD, et al, for the Assessment of Cardioversion Using Transesophageal Echocardiography Investigators. Use of transesophageal echocardiography to guide cardioversion in patients with atrial fibrillation. N Engl J Med 2001; 344: 1411-20.
7. Veinot JP, Harrity PJ, Gentile F, et al. Anatomy of the normal left atrial appendage. A quantitative study of age-related changes in 500 autopsy hearts: implications for echocardiographic examination. Circulation 1997; 96: 3112-5.
8. Khandheria BK, Seward JB, Tajik AJ. Critical appraisal of transesophageal echocardiography: limitations and pitfalls. Crit Care Clin 1996; 12: 235-51.
9. Dissman R, Voller H, Sorge M, Schroder K, Horstkotte D, Schultheiss HP. Possible errors in diagnosis of left atrial thrombosis in transesophageal echocardiography. Z Kardiol 1996; 85: 343-50.
10. Schiller NB, Shah PM, Crawford M, et al. Recommendations for quantitation of the left ventricle by two-dimensional echocardiography. American Society of Echocardiography Committee on Standards, Subcommittee on Quantitation of Two-Dimensional Echocardiograms. J Am Soc Echocardiogr 1989; 2: 358-67.
11. Chan SK, Kannam JP, Douglas PS, Manning WJ. Multiplane transesophageal echocardiographic assessment of left atrial appendage anatomy and function. Am J Cardiol 1995; 76: 528-30.
12. Pollick C, Taylor D. Assessment of left atrial appendage function by transesophageal echocardiography. Circulation 1991; 84: 223-31.
13. Santiago D, Warshofsky M, Mandri G, et al. Left atrial appendage function and thrombus formation in atrial fibrillation-flutter: a transesophageal echocardiographic study. J Am Coll Cardiol 1994; 24: 159-64.
14. Rubin DN, Katz SE, Riley MF, Douglas PS, Manning WJ. Evaluation of left atrial appendage anatomy and function in recent-onset atrial fibrillation by transesophageal echocardiography. Am J Cardiol 1996; 78: 774-8.
15. Fatkin D, Kuchar DL, Thoerburn CW, Feneley MP. Transesophageal echocardiography before and during direct current cardioversion of atrial fibrillation: evidence of "atrial stunning" as a mechanism of thromboembolic complications. J Am Coll Cardiol 1994; 23: 307-16.
16. Orsinelli DA, Pearson AC. Usefulness of multiplane transesophageal echocardiography in differentiating left atrial appendage thrombus from pectinate muscle. Am Heart J 1996; 131: 622-3.
17. Herzog E, Sherrid M. Bifid left atrial appendage with thrombus: source of thromboembolism. J Am Soc Echocardiogr 1998; 11: 910-5.
18. Bragato RM, La Marchesina U, Grimaldi A, Faletra F. Utilità di una sezione ecocardiografica sagittale dell'auricola di sinistra. Descrizione di un caso clinico. Ital Heart J Suppl 2001; 2: 1117-20.
19. Feigenbaum H. Echocardiography. Philadelphia, PA: Lea & Febiger, 1994: 24-5.
20. Appelbe AF, Walker PG, Yeoh JK, Bonitatibus A, Yoganathan AP, Martin RP. Clinical significance and origin of artifacts in transesophageal echocardiography in the thoracic aorta. J Am Coll Cardiol 1993; 21: 254-60.
21. Evangelista A, Garcia del Castilllo H, Gonzales-Alujas T, et al. Diagnosis of ascending aortic dissection by transesophageal echocardiography: utility of M-mode in recognizing artifacts. J Am Coll Cardiol 1996; 27: 102-7.
22. Manning WJ, Silverman DI, Katz SE, et al. Impaired left atrial mechanical function after cardioversion: relation to the duration of atrial fibrillation. J Am Coll Cardiol 1994; 23: 1535-40.
23. The Stroke Prevention and Atrial Fibrillation Investigators Committee on Echocardiography. Transesophageal echocardiographic correlates of thromboembolism in high-risk patients with nonvalvular atrial fibrillation. Ann Intern Med 1998; 128: 639-47.
24. Leung DY, Black IW, Crannery GB, Hopkins AP, Walsh WF. Prognostic implications of left atrial spontaneous echo contrast in nonvalvular atrial fibrillation. J Am Coll Cardiol 1994; 24: 755-62.
25. Stollberger C, Chnupa P, Kronik G, et al. Transesophageal echocardiography to assess embolic risk in patients with atrial fibrillation. ELAT Study Group. Embolism in Left Atrial Thrombi. Ann Intern Med 1998; 128: 630-8.
26. Jaber WA, Prior DL, Thamilarasan M, et al. Efficacy of anticoagulation in resolving left atrial and left atrial appendage thrombi: a transesophageal echocardiographic study. Am Heart J 2000; 140: 150-6.
27. Asinger RW, Koelher J, Pearce LA, et al. Pathophysiologic correlates of thromboembolism in nonvalvular atrial fibrillation: II. Dense spontaneous echocardiographic contrast (The Stroke Prevention in Atrial Fibrillation [SPAF III] Study). J Am Soc Echocardiogr 1999; 12: 1088-96.