Case reports

Noninvasive recognition of asymptomatic left anterior descending coronary artery stenosis in hypertensive left ventricular hypertrophy by conventional transthoracic Doppler echocardiography

Cesare de Gregorio, Francesco Saporito, Scipione Carerj, Sebastiano Coglitore, Giuseppe Oreto

Cardiology and Cardiovascular Rehabilitation Unit, Clinical and Experimental Department of Internal Medicine and Pharmacology, University Hospital, Messina, Italy

Key words:
Coronary artery disease; Coronary stenosis; Echocardiography; Echo-Doppler; Ventricular hypertrophy.

The noninvasive determination of the blood flow velocity in the left anterior descending coronary artery (LAD) at color Doppler echocardiography may provide useful clinical information. In this report, the authors describe the case of a patient with left ventricular hypertrophy secondary to hypertension in whom a critical but asymptomatic LAD stenosis was diagnosed at conventional echocardiography without resorting to pharmacological stress.

(Ital Heart J 2004; 5 (8): 629-631)

Received March 3, 2004; revision received April 20, 2004; accepted May 3, 2004.

Address:

Dr. Cesare de Gregorio

U.O. di Cardiologia e Riabilitazione Cardiologica Policlinico Universitario Via Consolare Valeria (Gazzi) 98125 Messina E-mail: cesaredegregorio1@virgilio.it

Introduction

The noninvasive measurement of the blood flow velocity in the left anterior descending coronary artery (LAD) at color Doppler echocardiography, either at rest or following pharmacological stress, may provide useful clinical information[1-3]. In the present report we describe the case of a patient in whom a critical but asymptomatic LAD stenosis was diagnosed at conventional Doppler echocardiography.

Case report

A 69-year-old male was admitted to our department due to recent-onset breathlessness and poorly controlled hypertension in spite of pharmacological treatment. The patient's history included mild hypercholesterolemia, cigarette smoking, and chronic pulmonary emphysema. Physical examination revealed a respiratory rate of 16 cycles/min, a blood pressure of 160/100 mmHg, and a heart rate of 70 b/min. Cardiac auscultation was negative.

Standard 12-lead ECG showed sinus rhythm, a P-R interval of 0.16 s, incomplete right bundle branch block, left axis deviation at -30° possibly representing left anterior hemiblock and negative T waves in leads V_1 to V_5 (Fig. 1).

Resting echocardiography showed mild concentric left ventricular hypertrophy, a left ventricular mass index – measured according to the American Society of Echocardiography method[4] – of 140 g/m^2, slight left atrial enlargement (end-systolic diameter 44 mm and systolic area 20 cm^2), impaired left ventricular diastolic relaxation, and normal wall motion at rest.

As per usual, once left ventricular hypertrophy is detected in our echo laboratory, especially in case of ST-T segment abnormalities, the LAD and, when possible, the intramural coronary arteries are investigated using high-frequency transducers.

In this patient, an aliasing color Doppler signal was disclosed in the middle segment of the LAD (Fig. 2). Blood flow measurement showed very high systolic and diastolic peak velocities (30.9 and 96.9 cm/s, respectively), with respect to the proximal (15.9 and 33.3 cm/s) and the distal (14.8 and 26.6 cm/s) segments of the same artery (Fig. 3 A-C), which hardly suggested the presence of significant coronary artery stenosis. The intramural coronary blood

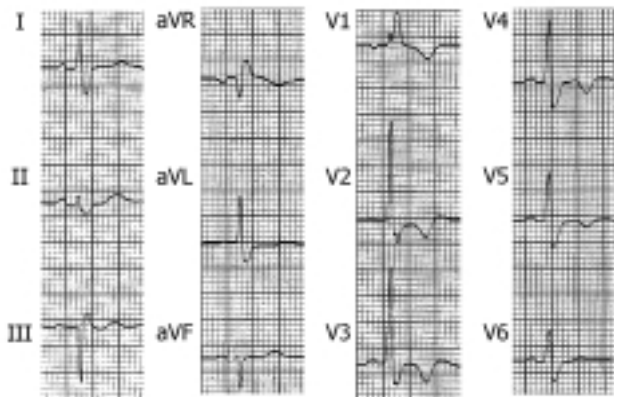

Figure 1. *Twelve-lead ECG performed at admission.*

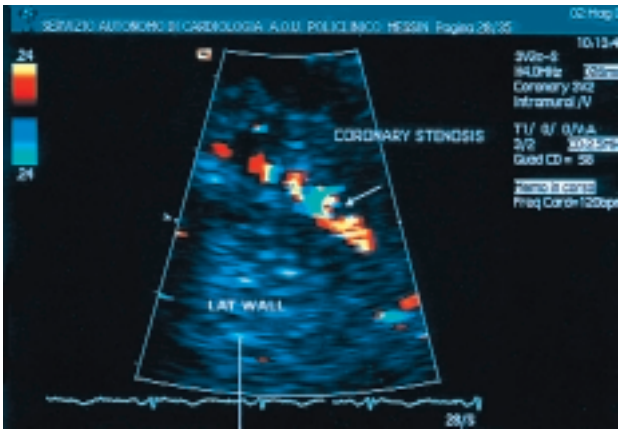

Figure 2. *Echocardiographic magnification of the stenotic left anterior descending coronary segment* (arrow). *Abnormal flow velocity pattern resulting in color Doppler aliasing.*

flow velocity was also investigated via the previously described method[5,6]. The peak and mean diastolic velocities were 91.6 and 64.9 cm/s respectively. When compared to a referring population of patients with left ventricular hypertrophy in our laboratory, a prolonged diastolic time-to-peak (105 ms in the patient vs 55 ± 20 ms in controls) along with systolic flow reversal were found (Fig. 3D).

In order to confirm our suspicion we then submitted the patient to dobutamine stress echo. Regional akinesia in the left ventricular apex, not associated with symptoms or relevant ECG changes, was revealed at the dose of 30 μg/kg/min. Coronary angiography indicated the presence of a stenosis ≥ 80% in the middle segment of the LAD (Fig. 4).

Discussion

In part confirming the method reliability established by Hozumi et al.[7] in another clinical context, the pre-

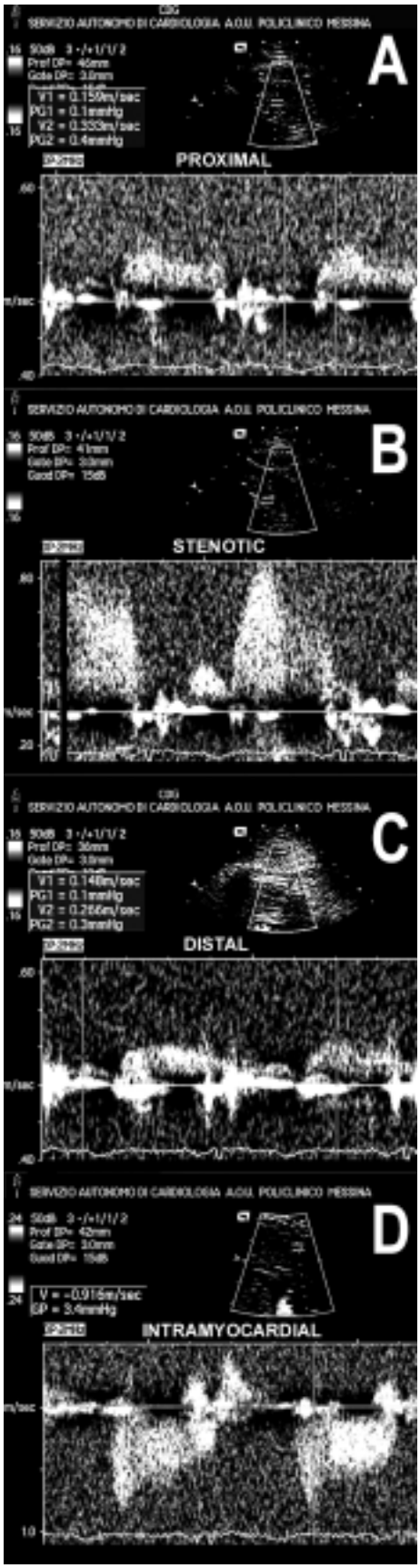

Figure 3. *Pulsed wave Doppler velocity sampling in three consecutive segments of the left anterior descending coronary artery. The blood flow velocities are significantly higher in the stenotic segment* (panel B) *than in the proximal* (panel A) *and the distal* (panel C) *ones.* Panel D *shows the velocity pattern in a small apical intramural coronary branch.*

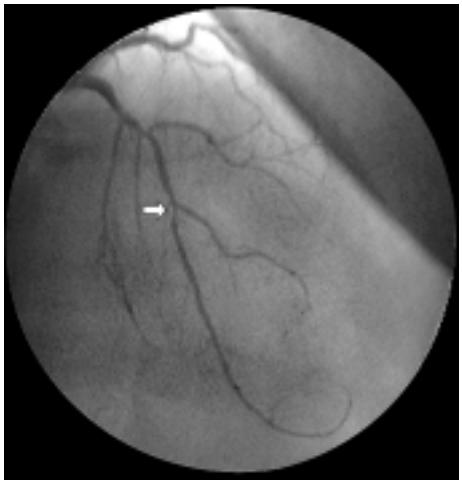

Figure 4. *Coronary angiography showing a stenosis (about 80%) in the middle segment of the left anterior descending coronary artery* (arrow).

sent report hints that high-resolution conventional Doppler echocardiography may, at times, reveal a critical coronary artery stenosis.

Doubtlessly extra information would have been provided by performing a coronary flow reserve[8] but, after dobutamine stress echo, it was mandatory to perform angiography.

Unfortunately, to date no studies have been designed in order to test the feasibility and reproducibility of this specific echocardiographic application, which appears to be appropriate only in a minority of patients, particularly in view of the increasing use of other more sophisticated techniques[9-11]. Furthermore, the intricate correlation between resting coronary velocity, blood flow reserve in the LAD, intramural behavior, myocardial perfusion and wall motion, surely necessitate further investigation, and Doppler echocardiography still plays a leading role in the clinical management of such patients.

On the other hand, only a few devices have been sufficiently upgraded to provide adequate (and stable) Doppler signals all along the coronary bed, and new innovative post-processing software are expected to be implemented.

All the same, after proper training the use of this application ought to be encouraged in patients with left ventricular hypertrophy and unclear ST-T wave abnormalities.

References

1. Eleuteri E, Scapellato F, Temporelli PL, Giannuzzi P. Evaluation of the left anterior descending coronary artery flow velocity by transthoracic echo-Doppler without contrast enhancement. Ital Heart J 2002; 3: 520-4.
2. Sieswerda GT, Yang L, Boo MB, Kamp O. Real-time perfusion imaging: a new echocardiographic technique for simultaneous evaluation of myocardial perfusion and contraction. Echocardiography 2003; 20: 545-55.
3. Cortigiani L, Coletta C, Bigi R, Amici E, Desideri A, Odoguardi L. Clinical, exercise electrocardiographic, and pharmacologic stress echocardiographic findings for risk stratification of hypertensive patients with chest pain. Am J Cardiol 2003; 91: 941-5.
4. Sahn DJ, DeMaria A, Kisslo J, Weyman A. Recommendations regarding quantitation in M-mode echocardiography: results of a survey of echocardiographic measurements. Circulation 1978; 58: 1072-83.
5. de Gregorio C, Recupero A, Grimaldi P, Coglitore S. Noninvasive assessment of intramyocardial coronary flow in hypertrophic cardiomyopathy by high-resolution Doppler echocardiography. Ital Heart J 2002; 3: 615-9.
6. de Gregorio C. Practical guidelines for the assessment of coronary artery flow velocity by Doppler-echocardiography. Italian Journal of Practice Cardiology 2003; 1: 17-22.
7. Hozumi T, Yoshida K, Akasaka T, et al. Value of acceleration flow and the prestenotic to stenotic coronary flow velocity ratio by transthoracic color Doppler echocardiography in noninvasive diagnosis of restenosis after percutaneous transluminal coronary angioplasty. J Am Coll Cardiol 2000; 35: 164-8.
8. De Simone L, Caso P, Severino S, et al. Reduction of coronary flow reserve non-invasively determined by transthoracic Doppler echocardiography as a predictor of left anterior descending coronary artery stenosis. Ital Heart J 2000; 1: 289-94.
9. Rossi R, Chiurlia E, Ratti C, Ligabue G, Romagnoli R, Modena MG. Noninvasive assessment of coronary artery bypass graft patency by multislice computed tomography. Ital Heart J 2004; 5: 36-41.
10. White RD, Setser RM. Integrated approach to evaluating coronary artery disease and ischemic heart disease. Am J Cardiol 2002; 90 (Suppl): 49L-55L.
11. Gaudio C, Vittore A, Mirabelli F, et al. Magnetic resonance coronary angiography: present clinical applications. Ital Heart J 2002; 3: 497-505.