Pulmonary embolism: diagnosis and follow-up by multislice computed tomography

Annachiara Aldrovandi, Romano Lutman*, Patrizia Presbitero

*Division of Interventional Cardiology, *Division of Radiology, Istituto Clinico Humanitas, Rozzano (MI), Italy*

(Ital Heart J 2004; 5 (10): 798-800)

Received June 15, 2004; revision received September 28, 2004; accepted September 29, 2004.

Address:

Dr.ssa
Annachiara Aldrovandi

Cardiologia Interventistica
Istituto Clinico Humanitas
Via Manzoni, 56
20089 Rozzano (MI)
E-mail:
aaldrovandi@libero.it

A 65-year-old male patient was admitted to our hospital 10 days after an episode of syncope complaining of effort dyspnea. An ECG showed sinus rhythm and negative T waves in leads V_1-V_3. An echocardiogram showed septal hypokinesia with a preserved left ventricular function; in view of this, the patient was referred to our center for coronary angiography, which showed normal coronary arteries.

A contrast-enhanced thoracic computed tomography (CT) was requested to evaluate the pulmonary arteries for pulmonary embolism. The exam was performed using a 16-slice (0.75 mm slice thickness) ECG-gated CT (Philips 8000MX, Eindhoven, The Netherlands) with a temporal resolution of 420 ms after infusion of 130 ml of iodinated contrast medium at 4 ml/s, during a brief apnea.

The reconstructed images showed embolism involving both pulmonary arteries at the proximal, lobar and segmental levels and extending to the left subsegmental pulmonary branches (Fig. 1). Cardiac imaging showed right ventricular dilation (Fig. 2).

Anticoagulation therapy was hence started. After 1 month, the dyspnea and ECG alterations had resolved. Repeat thoracic CT, performed following 3 months, showed almost complete resolution of the embolism at the proximal level, but persistence of emboli at the segmental and subsegmental levels (Fig. 3) and normalization of the right ventricular dimensions. A transthoracic echocardiogram showed normal systolic pulmonary artery pressure.

Pulmonary embolism is a disease with a potentially serious outcome if left untreated, with a mortality of 25 to 30%[1]; nevertheless, the diagnosis is frequently missed. In fact, the diagnosis is mostly based on a combination of laboratory tests and imaging techniques such as perfusion radionuclide scintigraphy and echocardiography which, in most cases, can only reveal indirect signs of embolism (right ventricular dilation and pulmonary hypertension), that are apparent only in case of severe pulmonary embolism. Conventional single-slice spiral CT has a limited spatial resolution. For this reason, it can explore only the proximal artery branches; in fact, false negative rates up to 30% have been reported in the literature[2].

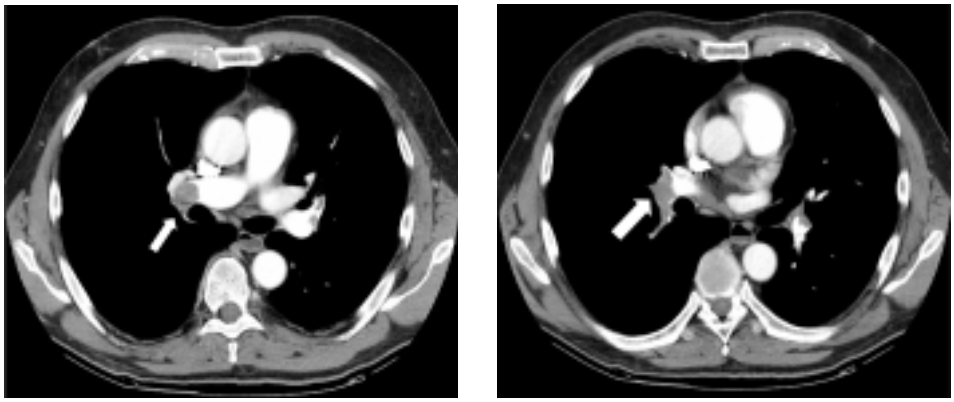

Figure 1. *Multislice computed tomography showing pulmonary embolism involving the left pulmonary artery* (arrow).

Figure 2. *Right ventricular dilation at multislice computed tomography.*

The gold standard is pulmonary angiography, but this is an invasive method, requires an experienced operator, is burdened by possible procedural complications, and is not widely available. Multislice CT has gained increased interest because of its higher spatial resolution (up to submillimeter slice thickness) compared to single-slice CT. The current generation of multislice scanners (4-, 8-, 10-, 16-slice) allows the acquisition of the entire chest volume in a short time (just a single breath-hold) and permits extensive visualization of the proximal, lobar and more distal pulmonary arteries (segmental and subsegmental levels), with an improved accuracy in the detection of peripheral emboli and a precise quantification of the extent of embolism. Furthermore, the short time of acquisition may facilitate the examination in patients with lung disease who could be markedly dyspnoic. Moreover, the CT scan permits the visualization of all the mediastinal and parenchymal structures, allowing the differential diagnosis with other diseases (i.e. pneumonia, lung cancer). Other signs of pulmonary embolism (pulmonary infarction, pleural effusion, vascular remodeling) may also be detected. It is also possible to combine the thoracic examination with venous CT angiography for the detection of deep venous thrombosis.

Using reconstructed images, it is possible to analyze and measure the right and left ventricular dimensions in the axial and 4-chamber views. This is another important piece of information taking into account that, as recently reported[3], right ventricular dilation is an unfavorable prognostic marker. It is known that acute pulmonary embolism may evolve to chronic thromboembolic pulmonary hypertension (CTPH), whose incidence at 2 years of follow-up is estimated to range between 3.8 and 5%[4,5]. This very subtle disease is due to the presence of undiagnosed, unresolved distal pulmonary emboli which are not visible at standard single-slice CT. CTPH is a disease with a high morbidity and mortality. For this reason, having a reliable, non-invasive method for the diagnosis of patients who are evolving to this entity could be very important. Such patients have to be managed with chronic anticoagulation therapy or with surgical pulmonary endarterectomy.

Echocardiography is usually the first-line examination for the serial evaluation of the function and dimension of the right cardiac chambers and to measure the pulmonary pressure. However, using this method the diagnosis of CTPH may be reached only when pulmonary hypertension is already established. Multislice CT could be a useful method for the direct evaluation of the degree of resolution of pulmonary embolism before progression (*in situ* thrombus apposition, pulmonary vasoconstriction) to pulmonary hypertension. In this case report, echocardiography was suggestive of a normal pulmonary artery systolic pressure, but 3-month multislice CT showed incomplete resolution of the emboli. For this reason, the patient was maintained in anticoagulation therapy indefinitely.

We suggest performing a CT scan 3 months after the initial diagnosis of pulmonary embolism, because all emboli should normally resolve within this time lapse. Pulmonary scintigraphy, which is the recommended

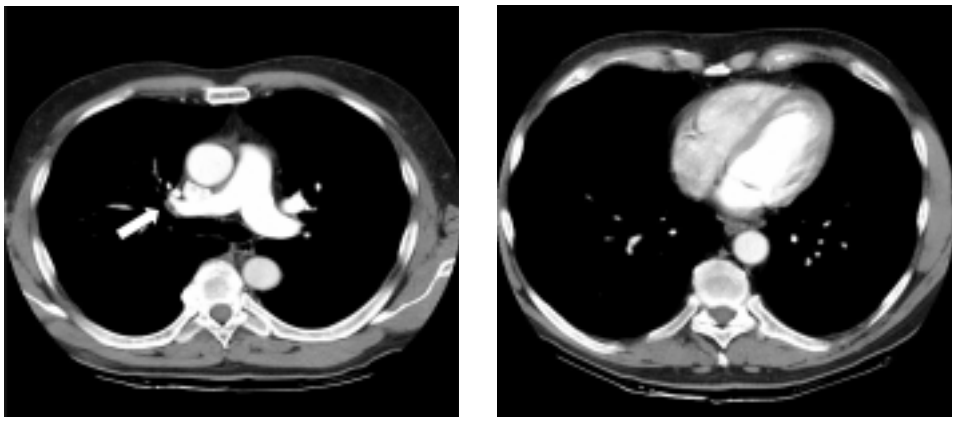

Figure 3. *Three months after anticoagulation therapy, multislice computed tomography showed almost complete resolution of the pulmonary artery thrombosis (a thin layer of thrombus in the mid segment of the left pulmonary artery is still present,* arrow*) and normalization of the right ventricular dimensions.*

examination to confirm thrombus resolution carries an amount of radiation comparable to that of multislice CT and does not provide an anatomical picture of the disease.

Anatomical study is important to establish an indication for surgical therapy. The feasibility of pulmonary endarterectomy depends on the location of the disease and is possible if the embolus involves only the proximal pulmonary branches. Multislice CT allows the precise determination of the extent and location of the emboli and simultaneously a differential diagnosis with other possible causes of pulmonary hypertension (cancer, pulmonary angiosarcoma, vasculitis, mediastinal fibrosis, restrictive or obstructive lung disease).

Multislice CT is a non-invasive method with a very low rate of complications; therefore, it constitutes a useful tool for the diagnosis of acute pulmonary embolism and for patient follow-up after anticoagulation therapy.

References

1. Task Force on Pulmonary Embolism, European Society of Cardiology. Guidelines on diagnosis and management of acute pulmonary embolism. Eur Heart J 2000; 21: 1301-36.
2. Drucker EA, Rivitz SM, Shepard JA, et al. Acute pulmonary embolism: assessment of helical CT for diagnosis. Radiology 1998; 209: 235-41.
3. Quiroz R, Kucher N, Schoepf UJ, et al. Right ventricular enlargement on chest computed tomography: prognostic role in acute pulmonary embolism. Circulation 2004; 109: 2401-4.
4. Pengo V, Lensing AW, Prins MH, et al, for the Thromboembolic Pulmonary Hypertension Study Group. Incidence of chronic thromboembolic pulmonary hypertension after pulmonary embolism. N Engl J Med 2004; 350: 2257-64.
5. Ribeiro A, Lindmarker P, Johnsson H, Juhlin-Dannfelt A, Jorfeldt L. Pulmonary embolism: one-year follow-up with echocardiography Doppler and five-year survival analysis. Circulation 1999; 99: 1325-30.