Case reports

Ablation of left atrial flutter in a patient surgically treated for atrial fibrillation. Does it indicate a possible hybrid approach?

Gaetano Barbato, Giuseppe Marinelli*, Valeria Carinci, Bruno Chiappini*, Francesco Pergolini, Daniele Bracchetti, Giuseppe Di Pasquale

*Cardiology Unit, Maggiore Hospital, *Cardiovascular Surgery Department, S. Orsola Hospital, Bologna, Italy*

Key words:
Atrial flutter; Mapping; Radiofrequency ablation.

Surgical treatment of atrial fibrillation (AF) has a high success rate and nowadays simpler and faster procedures have been proposed. The following is a description of the case of a patient who, after a modified Maze procedure, developed an atypical left atrial flutter and underwent a successful radiofrequency ablation procedure.

A 71-year-old male underwent surgical biological valve replacement and a concomitant modified Maze procedure. After surgery the patient developed a persistent atrial arrhythmia with severe symptoms and refractory to any drug. For this reason, an electrophysiological study was planned. We performed a three-dimensional atrial mapping using the real-time position management system (Boston Scientific). Right atrial mapping indicated an early activation area on the septum. After transseptal puncture, left atrial mapping showed a reentry circuit around the mitral annulus with positive entrainment. A linear lesion was made between the mitral annulus and the superior right pulmonary vein and sinus rhythm was restored. After 7 months of follow-up the patient is asymptomatic and still in stable sinus rhythm.

In conclusion, the follow-up of surgical AF may be improved by close collaboration between the surgeon and electrophysiologist. The available data suggest that a combined surgical and percutaneous approach could be the strategy of choice.

(Ital Heart J 2004; 5 (12): 941-945)

Received June 15, 2004; revision received October 20, 2004; accepted October 21, 2004.

Address:

Dr. Gaetano Barbato

Unità Ospedaliera di Cardiologia Ospedale Maggiore-Pizzardi Largo Nigrisoli, 2 40133 Bologna E-mail: Gaetano.Barbato@ausl.bologna.it

Background

The incidence of atrial fibrillation (AF) among patients undergoing mitral valve surgery is estimated to be about 50%. The Maze procedure is very effective in converting this arrhythmia to stable sinus rhythm[1,2]. However, the standard Maze procedure ("cut-and-sew" technique) is complex and time-consuming. In recent years much simpler surgical approaches have been developed, based on a combination of device-assisted ablation (radiofrequency-RF, microwave, cryoablation) and various lesion sets limited to the left atrium and involving the pulmonary vein ostia[3]. Despite a lower success rate (60 to 80%), the simplicity of these approaches reduces the surgical time and renders treatment of a larger number of patients possible. With the increasing use of surgery for the treatment of AF, the problem of post-procedure follow-up and eventual relapse management has become rather urgent[4-6].

We report a case of atypical atrial flutter, refractory to any pharmacological treatment or cardioversion, that developed after a modified Maze procedure and that was successfully treated with RF ablation after three-dimensional mapping using the real-time position management (RPM) system.

Case report

The patient was a 71-year-old male with a clinical history of dyspnea (NYHA functional class III) and palpitations. At 53 years of age, he had been submitted to commissurotomy of the mitral valve for rheumatic mitral stenosis. Subsequently he remained well until 2 years before the procedure in question, when he became progressively more symptomatic and had to be repeatedly hospitalized for persistent AF and heart failure.

Preoperative echocardiography (sinus rhythm) revealed severe mitral stenosis, unsuitable for percutaneous valvuloplasty, and moderate aortic regurgitation, moderate left atrial dilation (M-mode 56 mm), a normal left ventricular function, and mod-

erate pulmonary hypertension. Coronary angiography was normal. In view of this, mitral and aortic valve replacement (bioprosthesis) and a concomitant modified Maze procedure were planned.

Radiofrequency surgical ablation. The operation was performed via a conventional median sternotomy[7]. Extracorporeal circulation was instituted using the bicaval and aortic incannulation, under moderate hypothermia (32°C); myocardial protection was assured by antegrade crystalloid cardioplegia. RF ablation was performed under direct vision through a left atrial incision, which allowed full access to the mitral annulus and to the orifices of the four pulmonary veins. RF energy was delivered in a unipolar mode between an external backplate and the tip of a specifically designed ablation probe (Cobra Flex, Boston Scientific, San José, CA, USA) at a temperature of 70°-80°C for a period of 2 min in the left atrium and for 90 s in the right atrium. The RF ablation scheme consisted of applying the probe around the pulmonary vein ostia at a distance of 5 mm from the orifices in such a manner that a connection was established between these structures. The ablation was then continued to the mitral valve annulus and into the left atrium. The left atrial appendage was totally excised and sutured with 4/0 Prolene (Ethicon, Somerville, NJ, USA). In the right atrium the probe was applied between the inferior vena cava and the tricuspid annulus, posteriorly to the coronary sinus, thus isolating the isthmus (Fig. 1). The lesion set is always comprehensive of right atrial flutter. Sinus rhythm was documented immediately after RF ablation.

In the early postoperative period the patient presented with a few episodes of AF and medical therapy with sotalol and digitalis was initiated. After a few days he developed an extremely refractory atrial arrhythmia. The ECG showed a regular atrial pattern, similar to that of atrial tachycardia or atypical atrial flutter, sometimes indistinguishable from AF. The ventricular rate was stable at about 115 b/min (Fig. 2). Attempts at restoring sinus rhythm failed and the patient was sent home on rate control therapy (verapamil, carvedilol and warfarin). At follow-up the patient was found to still have the arrhythmia persisted and his symptoms included severe palpitations and dyspnea. Echocardiography revealed that the ejection fraction was significantly decreased (35%), but that the bioprosthesis was functioning well. For this reason the patient was referred to our center and an electrophysiological study was planned.

Electrophysiological study and radiofrequency catheter ablation. The study was performed using the RPM three-dimensional mapping system (EP Technologies, Boston Scientific, San José, CA, USA). This system is based on an ultrasound technique. It uses two reference catheters (one in the coronary sinus or right atrial appendage and one in the right ventricle), and one mapping/ablation catheter. The catheters are equipped with a series of intercommunicating ultrasound transmitters and receivers. The collected data are transferred to the mapping computer and processed to provide a real-time display of the catheters' position and to reconstruct a three-dimensional anatomy of the heart. A more detailed description has been published previously[8,9].

The reference catheters were positioned in the right ventricular apex and coronary sinus. For purposes of mapping/ablation, a 7F, 4 mm steerable cooled tip, closed system catheter (Chili-RPM) was used.

We performed a three-dimensional atrial mapping using the RPM system. Although the activation pattern in the coronary sinus suggested a left atrial arrhythmia substrate, right atrial mapping was all the same performed to confirm the diagnosis. An early activation area was identified on the septum (Bachmann bundle area; Fig. 3) but the entrainment from this area was negative. After transseptal puncture, left atrial mapping revealed the presence of a reentry circuit around the mitral annulus and the entrainment (performed from dif-

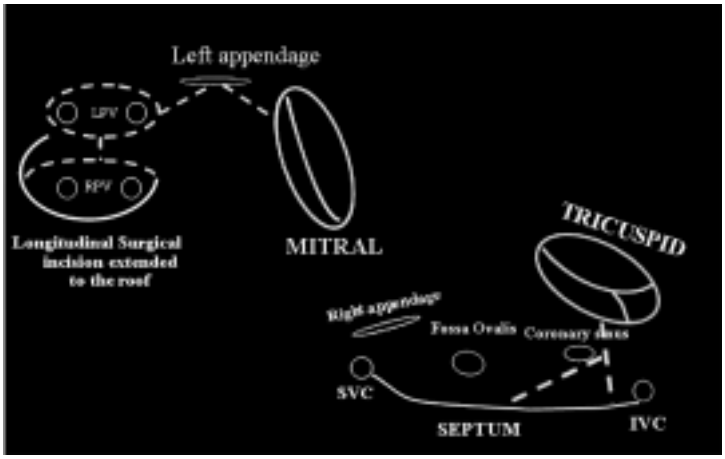

Figure 1. *The lesion set of surgical procedure, comprehensive of right atrial flutter lesion and concomitant excision of the left atrial appendage. IVC = inferior vena cava; LPV = left pulmonary vein; RPV = right pulmonary vein; SVC = superior vena cava.*

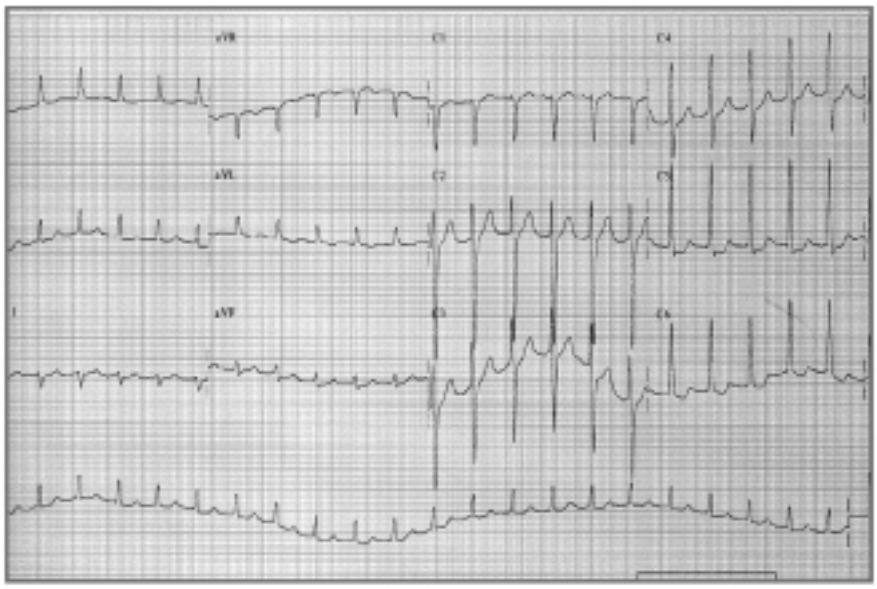

Figure 2. *Atrial tachycardia at ECG.*

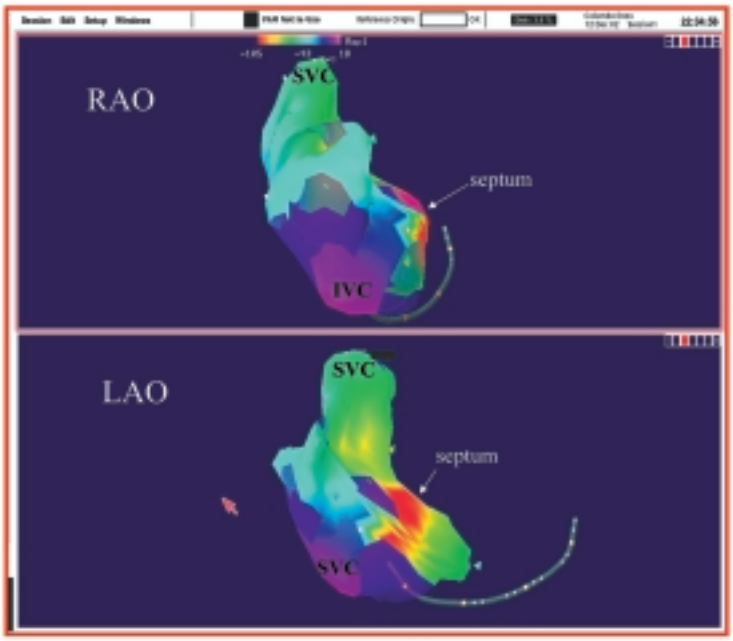

Figure 3. *Isochronal activation map of the right atrium (right anterior oblique-RAO and left anterior oblique-LAO projections) acquired by means of the real-time position management system. The* red color *shows the earlier activation area and the* purple *one the latest (see color bar* on the top*). The earliest activation site is immediately recognizable on the septum. IVC = inferior vena cava; SVC = superior vena cava.*

ferent annulus points) was positive (Fig. 4). An initial attempt to ablate the area between the inferior left pulmonary vein and mitral annulus was unsuccessful. RF was delivered under power control starting with 20 W and increasing by 5 W increments until a temperature of 40°C was reached. In that area only low amplitude signals were recorded (probably due to the presence of scar tissue) and it was impossible to verify the RF effect on the tissue (signal amplitude reduction). For this reason, we preferred creating a linear lesion (Fig. 5) starting from the mitral annulus and proceeding toward the superior right pulmonary vein. In this way we initially achieved a longer tachycardia cycle length (after about 2 cm of ablation). Further ablation in the same direction resulted in the restoration of sinus rhythm (Fig. 6).

Following the completion of this procedure, programmed atrial stimulation up to three extra beats with a basic cycle length of 600, 500 and 400 ms did not induce any arrhythmias.

After 6 months of follow-up the patient was still asymptomatic and in stable sinus rhythm without any antiarrhythmic therapy. Echocardiography confirmed

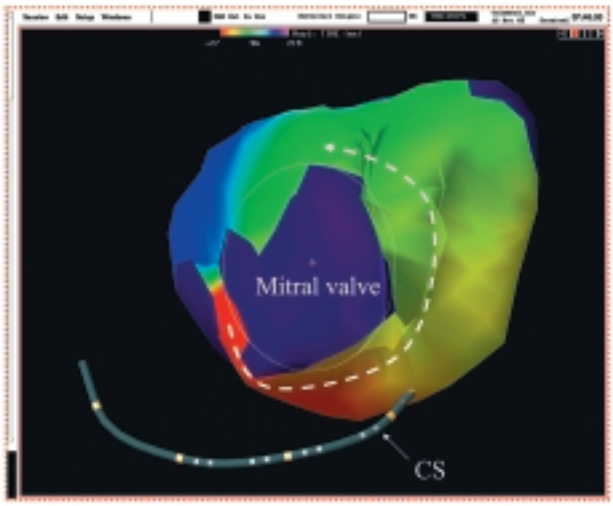

Figure 4. *Isochronal activation real-time position management map of the left atrium during tachycardia. A single reentrant circuit is present around the mitral annulus. The entrainment from different annulus points was positive. CS = coronary sinus catheter.*

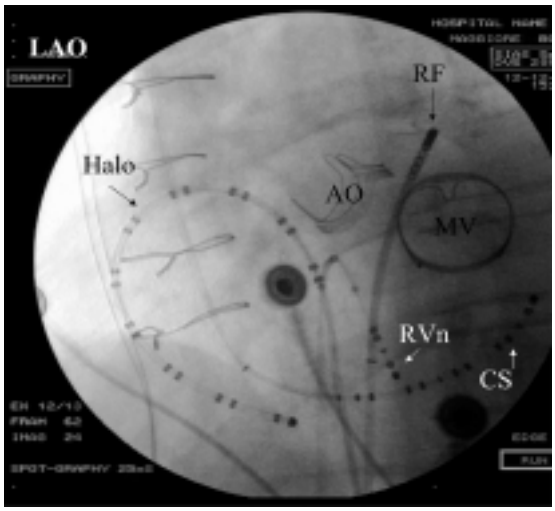

Figure 5. *Fluoroscopic left anterior oblique (LAO) image showing the Halo catheter in the right atrium and real-time position management catheter position. The radiofrequency (RF) catheter is onto the critical ablation site. AO = aortic bioprosthesis; CS = coronary sinus catheter; MV = mitral bioprosthesis; RVn = right ventricular catheter.*

an improved left ventricular function (ejection fraction 50%) and the anticoagulant regimen was suspended. To date (12 months later), the patient or his family have not referred any cerebral events.

Discussion

In recent years, interest in the surgical approach to AF has increased. Various techniques including linear lesion schema, an open-heart or minimally invasive approach and epicardial or endocardial lesions have been described in the literature[3-5,10-13]. These new approaches yielded different results depending on several factors (population selected, arrhythmia substrate, lesion set) but generally resulted in a success rate ranging between 60 and 80%.

In patients who have undergone surgery for AF it is not uncommon to observe "organized" arrhythmias during follow-up[5,14].

In case of an approach limited to the left atrium, the incidence of right atrial flutter is about 5-10%; for this reason, several surgeons (including those at our institution) add a right atrial approach in the procedural lesion set.

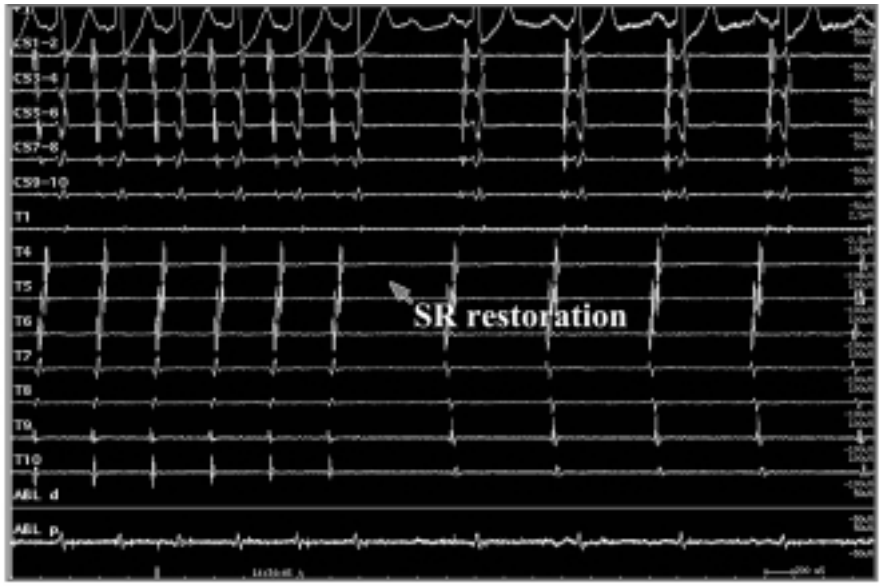

Figure 6. *Real-time position management record showing sinus rhythm (SR).* From the top: *ECG line, coronary sinus lines (CS1-CS10), Halo (T1-T10), distal (ABL d) and proximal (ABL p) ablator tracking catheter. The Halo potential activation sequence shows the change from a typical left atrial flutter activation pattern to SR.*

Even atypical flutter may be documented in these patients. The first case of left atrial flutter after a Maze procedure was reported by Cox and Ad[15]. This highlighted the importance of the left atrial isthmus lesion. It was a persistent flutter, very similar to the one we describe, and the arrhythmia circuit was around the mitral annulus.

Long and incomplete linear lesions in the atria may create an ideal substrate for intra-atrial reentry. The ECG pattern of atypical flutter may be misleading because it could mimic AF. For this reason, an electrophysiological evaluation is recommended in case of recurrences after a Maze procedure.

It is difficult to estimate the real incidence of post-surgical atrial tachycardia in these patients. The incidence of atypical flutter following surgery is reported to be about 2.5%[4,5,12].

There is some concern about the feasibility and safety of a transseptal procedure in patients with a valve prosthesis, and, to our knowledge, this is one of the first cases reported. However, in our experience the procedure may be safely performed by ensuring appropriate anticoagulation and caution during catheter movement.

Incisional arrhythmia mapping requires a three-dimensional mapping system[6,16-18] and at our institute we use a RPM mapping system which is a novel contact mapping system based on an ultrasound ranging technique and integrated with a traditional recording system[8,9,19]. The system, which simultaneously records endocardial signals and the position of the tracking catheter, permits a three-dimensional activation map reconstruction. Once the map is available, it is possible to study the arrhythmia circuit, to navigate inside without fluoroscopy and to locate the RF ablator at a specific point, corresponding to the specific previously recorded endocardial potential. The map, isochronal and isopotential, may be updated on short arrhythmia episodes or even on a single atrial extrasystole allowing the ablation even of a non-sustained arrhythmia. The system software is simple to use and the learning curve is particularly short.

In conclusion, surgical treatment of AF should be considered for patients undergoing surgery for other reasons. These patients need careful follow-up in order to check for the recurrence of AF or other arrhythmic events that could be diagnosed at electrophysiological evaluation including three-dimensional mapping. The available data suggest that a combined surgical and percutaneous approach could be the strategy of choice.

The presence of a valve prosthesis (biological or mechanical) has been considered a contraindication for some percutaneous procedures but, in our experience, these cases may be safely studied and treated.

References

1. Cox JL, Ad N, Palazzo T, et al. The Maze-III procedure combined with valve surgery. Semin Thorac Cardiovasc Surg 2000; 12: 53-5.
2. Cox JL, Niv A, Palazzo T, et al. Current status of the Maze procedure for the treatment of atrial fibrillation. Semin Thorac Cardiovasc Surg 2000; 12: 15-9.
3. Gillinov AM, McCarthy PM, Marrouche N, Natale A. Contemporary surgical treatment for atrial fibrillation. Pacing Clin Electrophysiol 2003; 26 (Part 2): 1641-4.
4. Manasse E, Gaita F, Ghiselli S, et al. Cryoablation of the left posterior atrial wall: 95 patients and 3 years of mean follow-up. Eur J Cardiothorac Surg 2003; 24: 731-40.
5. Benussi S, Nascimbene S, Agricola E, et al. Surgical ablation of atrial fibrillation using the epicardial radiofrequency approach: midterm results and risk analysis. Ann Thorac Surg 2002; 74: 1050-7.
6. Duru F, Hindricks G, Kottkamp H. Atypical atrial flutter after intraoperative radiofrequency ablation of chronic atrial fibrillation: successful ablation using three-dimensional electroanatomic mapping. J Cardiovasc Electrophysiol 2001; 12: 602-5.
7. Chiappini B, Martin-Suarez S, LoForte A, Di Bartolomeo R, Marinelli G. Surgery for atrial fibrillation using radiofrequency catheter ablation. J Thorac Cardiovasc Surg 2003; 126: 1788-91.
8. de Groot N, Bootsma M, van der Velde ET, Schalij MJ. Three-dimensional catheter positioning during radiofrequency ablation in patients: first application or real-time position management system. J Cardiovasc Electrophysiol 2000; 11: 1183-92.
9. Schreiek J, Ndrepepa G, Zrenner B, et al. Radiofrequency ablation of cardiac arrhythmias using a three-dimensional real-time position management and mapping system. Pacing Clin Electrophysiol 2002; 25: 1699-707.
10. Deneke T, Khargi K, Grewe PH, et al. Left atrial versus biatrial Maze operation using intraoperatively cooled-tip radiofrequency ablation in patients undergoing open-heart surgery: safety and efficacy. J Am Coll Cardiol 2002; 39: 1644-50.
11. Sueda T, Nagata H, Orihashi K, et al. Efficacy of a simple left atrial procedure for chronic atrial fibrillation in mitral valve operations. Ann Thorac Surg 1997; 63: 1070-5.
12. Sie HT, Beukema WP, Ramdat Misier AR, Elvan A, Ennema JJ, Wellens HJ. The radiofrequency modified Maze procedure. A less invasive surgical approach to atrial fibrillation during open-heart surgery. Eur J Cardiothorac Surg 2001; 19: 443-7.
13. Mohr FW, Fabricius AM, Falk W, et al. Curative treatment of atrial fibrillation with intraoperative radiofrequency ablation: short-term and midterm results. J Thorac Cardiovasc Surg 2002; 123: 919-27.
14. Usui A, Inden Y, Mizutani S, Takagi Y, Akita T, Ueda Y. Repetitive atrial flutter as a complication of the left-sided simple maze procedure. Ann Thorac Surg 2002; 73: 1473-9.
15. Cox JL, Ad N. The importance of cryoablation of the coronary sinus during the Maze procedure. Semin Thorac Cardiovasc Surg 2000; 12: 20-4.
16. Spitzer SG, Karolyi L, Rammler C, Otto T, Jung F. Ablation of typical atrial flutter using a three-dimensional ultrasound mapping system. J Interv Card Electrophysiol 2003; 8: 181-5.
17. Villacastin J, Perez-Castellano N, Moreno J, Gonzales R. Left atrial flutter after radiofrequency catheter ablation of focal atrial fibrillation. J Cardiovasc Electrophysiol 2003; 14: 417-21.
18. Leonelli FM, Tomassoni G, Richey M, Natale A. Usefulness of three-dimensional non-fluoroscopic mapping in the ablation of atrial flutter. Ital Heart J 2002; 3: 360-5.
19. Friedman PA. Novel mapping techniques for cardiac electrophysiology. Heart 2002; 87: 575-82.