Stent repair of aortic perianastomotic leak after aortic arch and descending aorta replacement

Emanuela Angeli, Davide Pacini, Sofia Martin-Suarez, Andrea Dell'Amore, Rossella Fattori*, Roberto Di Bartolomeo

*Department of Cardiac Surgery, *Cardiovascular Unit, Department of Radiology, University of Bologna, Bologna, Italy*

Key words:
Aneurysm; Aorta; Cardiac surgery; Stents.

Surgical treatment of the thoracic aorta combined with endovascular stent grafting may be an interesting approach to diseases of the thoracic aorta in high-risk patients.

A patient with a chronic post-dissection aneurysm of the aortic arch and proximal descending aorta developed, after surgery, a perianastomotic leak of the distal suture of the graft. We successfully treated the leak by means of an endovascular stent graft procedure. These combined procedures may be useful to resolve surgical complications particularly in case of high operative risk.

(Ital Heart J 2004; 5 (12): 951-953)

Received May 6, 2004; revision received October 11, 2004; accepted October 12, 2004.

Address:

Dr.ssa Emanuela Angeli

Divisione di Cardiochirurgia Università degli Studi Policlinico S. Orsola-Malpighi Via Massarenti, 9 40138 Bologna E-mail: apierangeli@orsola-malpighi.med.unibo.it

Introduction

The high mortality and morbidity related to open surgical repair of diseased thoracic aortic segments, despite the continuous advances in surgical techniques, is well known[1-3]. At the same time, the life expectancy of untreated patients is very limited.

The endovascular treatment of descending thoracic aortic pathology offers a therapeutic alternative in high surgical risk patients, particularly in the presence of previous surgical repair of the thoracic aorta[1,4,5]. This procedure is potentially less invasive and less expensive and may reduce the surgical time, the blood loss and the impact of surgical replacement on the patient.

We present a difficult case in which, after open surgical repair of the aortic arch and descending thoracic aorta, we resorted to an endovascular stent to resolve a perianastomotic leak of the distal suture of the graft, with excellent results.

Case report

A 50-year-old male with a history of cigarette smoking and hypertension was admitted to our hospital with a diagnosis of a chronic post-dissection aneurysm of the aortic arch and proximal segment of the descending aorta. In 1993, he had developed an acute type A aortic dissection and was submitted to a Bentall's procedure.

Control computed tomography (CT) scan showed an increasing dilation of the false lumen of the native ascending aorta and the aortic arch extending to the proximal segment of the descending aorta.

In September 2000 he was referred to our hospital for surgical evaluation. A CT scan showed a dilation of the ascending aorta starting from the distal anastomosis of the Bentall's graft and a large aneurysm of the distal aortic arch extending to the proximal half of the descending thoracic aorta. Aortography showed the origin of the epiaortic vessels in the true lumen of the aorta.

In view of the risk of rupture of the aneurysm it was decided to submit the patient to surgery in spite of his high operative risk. He was submitted to aortic arch and descending aorta replacement.

Access to the aorta was gained through a medial sternotomy. Extracorporeal circulation was achieved through the right femoral artery and right atrium, with drainage of the right superior pulmonary vein. We used the Kazui technique to apply antegrade perfusion, following occlusion of the left subclavian artery with a Fogarty catheter.

The dissecting lesion was extended from the previous distal suture of the composite graft to the proximal segment of the descending thoracic aorta. In view of the difficult surgical approach we had to perform a fourth intercostal space left thoracotomy.

A 28 mm Vascutek graft, type Gelweave Plexus 4 (Inchinnan, Renfrewshire, Scotland), was used for arch replacement and for insertion into the descending thoracic aorta.

The distal end-to-end anastomosis was performed between T5-T6 using a single Teflon strip to support the aortic arterial wall.

After reimplantation of the subclavian artery on the arch graft, the aorta was clamped and antegrade perfusion started through the fourth branch of the Vascutek graft.

The proximal anastomosis was made between the previous prosthesis and the new graft. Subsequently the aorta was declamped. The arch branches of the aorta on the arch graft were replaced during rewarming. The extracorporeal circulation time was 118 min and the length of circulatory arrest was 3 min with a mean temperature of 22°C.

Four weeks after discharge the patient was readmitted to another hospital with recurrent high fever and treated with selective antibiotical therapy for 3 weeks.

Magnetic resonance performed in our hospital after 2 months showed a massive blood periprosthetic infiltration coinciding with the site of the distal descending aorta anastomosis and residual dissection of the abdominal aorta with a pervious false lumen (Fig. 1). He was selected for endovascular treatment on the basis of a suitable anatomy for stent graft placement: a diameter of the distal neck of 30 mm, a diameter of the femoral arteries > 9 mm, and no severe aorto-iliac tortuosity.

In November 2000 we performed endovascualr stent grafting of the descending aorta. The procedure was performed using a Talent World medical graft 11 cm in length and with a diameter of 32 mm. Access was gained through the right femoral artery under general anesthesia. After administration of a bolus of 5000 IU of heparin, the endovascular stent system was inserted over the guide wire through a transverse arteriotomy and advanced under fluoroscopic and transesophageal echocardiographic guidance. Having carefully checked the status of the aortic wall and the diameter of the neck sites, the exact placement site was selected on the basis of the transesophageal echocardiographic and angiographic findings. Just before the device was released, vasodilators (sodium nitroprusside and calcium channel blockers) were intravenously administered to decrease the systolic pressure to 50-70 mmHg. We did not perform balloon inflation. Intraoperative digital subtraction angiography and transesophageal echocardiography revealed complete exclusion of the pseudoaneurysm. Magnetic resonance, performed 4 days later, confirmed the exclusion of all the flow within the aneurysm (Fig. 2).

A CT scan performed before discharge confirmed complete exclusion of the descending thoracic aortic pseudoaneurysm.

In December 2001 the patient was admitted to our hospital for elective open repair of an abdominal aortic aneurysm. He was successfully treated and was discharged after 8 days.

CT scan follow-up control confirmed complete exclusion of the pseudoaneurysm.

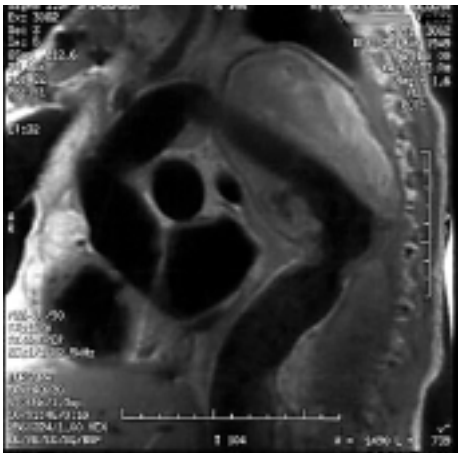

A

B

Figure 1. *T1-weighted magnetic resonance spin-echo sequence* (A) *and magnetic resonance angiography multiplanar volume reconstruction* (B) *on an oblique sagittal plane showing a wide periprosthetic collection starting from the distal anastomosis.*

Discussion

Patients with combined ascending and aortic arch aneurysms and distal disease of the aorta treated with surgical graft replacement, have only a 46% 5-year survival rate[3].

In view of the persistent perioperative morbidity and mortality, endovascular stent graft placement was intro-

Figure 2. *T1-weighted magnetic resonance spin-echo sequence on an oblique sagittal plane performed 1 year after the endovascular procedure and showing a significant reduction in the size of the periprosthetic collection without evidence of any perigraft leak.*

duced into clinical practice as a minimally invasive and potentially safer treatment for diseases of the descending aorta with a reduced risk of spinal cord ischemia[4].

In our patient the conventional surgical approach with redo left thoracotomy to repair the periprosthetic leak would have been associated with a high risk of operative and postoperative complications.

The solution to the problem of severe surgical complications consisted in resorting to an endovascular approach. The stent graft was the lowest-risk solution for the resolution of the aortic pseudoaneurysm. Besides the lower rates of morbidity and mortality[3,4,6], this procedure also reduced the surgical time, the blood loss, the intensive care unit and hospital stay, and the risk of paraplegia. The patient was discharged after 8 days and spent < 24 hours in the intensive care unit.

A CT control scan performed 1 month later showed the satisfactory outcome of the stent procedure.

We resolved the problem of the subsequent abdominal aneurysm by resorting to a relatively easy surgical approach consisting of prosthetic substitution of the abdominal aorta.

As shown in our report, in case of multiple diseases of the aorta necessitating difficult surgical redo or high-risk procedures, combined open surgery and stent graft procedures may reduce the surgical risks, the length of hospitalization and even the hospital costs with significant advantages for the patients.

References

1. Fann JI, Miller DC. Endovascular treatment of descending thoracic aortic aneurysms and dissections. Surg Clin North Am 1999; 79: 551-74.
2. Ergin MA, Galla JD, Lansman SL, Quintana C, Bodian C, Griepp RB. Hypothermic circulatory arrest in operations on the thoracic aorta: determinants of operative mortality and neurologic outcome. J Thorac Cardiovasc Surg 1994; 107: 788-99.
3. Fann JI, Dake MD, Semba CP, Liddell RP, Pfeffer TA, Miller DC. Endovascular stent-grafting after arch aneurysm repair using the “elephant trunk”. Ann Thorac Surg 1995; 60: 1102-5.
4. Thurner SA, Grabenwoger M. Endovascular treatment of thoracic aortic aneurysms: a review. Eur Radiol 2002; 12: 1370- 87.
5. Dake MD, Miller DC, Mitchell RS, Semba CP, Moore KA, Sakai T. The “first generation” of endovascular stent-grafts for patients with aneurysms of the descending thoracic aorta. J Thorac Cardiovasc Surg 1998; 116: 689-704.
6. Vermeulen F, Schepens M, de Valois J, Wijers L, Kelder J. The Hemashield woven prosthesis in the thoracic aorta: a prospective computer tomography follow-up study. Cardiovasc Surg 2001; 9: 580-5.