Compression repair versus low-dose thrombin injection for the treatment of iatrogenic femoral pseudoaneurysm: a retrospective case-control study

Gian Battista Danzi, Marco Sesana, Cinzia Capuano, Roberto Baglini, Raffaello Bellosta*, Luca Luzzani*, Claudio Carugati*, Antonio Sarcina*

*Interventional Cardiology Unit, *Vascular Surgery Unit, Poliambulanza Hospital, Brescia, Italy*

Key words:
Pseudoaneurysm; Thrombin; Ultrasonography.

Background. **It has been shown that thrombin injection is a safe and effective technique for the treatment of iatrogenic femoral pseudoaneurysm. The aim of this study was to evaluate and compare the use of ultrasound-guided low-dose thrombin injections with ultrasonographically-guided compression repair in the treatment of iatrogenic femoral arterial pseudoaneurysm.**

Methods. **We compared two cohorts of patients treated for iatrogenic femoral pseudoaneurysm: the first included 38 patients who underwent ultrasonographically-guided compression repair as a first-step approach between January 1998 and November 2002; the second included 21 patients treated with ultrasound-guided low-dose thrombin injection between December 2002 and December 2003**.

Results. **Both groups had similar demographic characteristics and aneurysm sizes (p = 0.72). Compression was successful in 24/38 patients (63%); the 14 persistent aneurysms were surgically repaired (37%). The primary thrombin injection of a mean dose of 185 ± 95 U/ml (range 100-400 U/ml) successfully obliterated all of the 21 pseudoaneurysms (success rate 100 vs 63% in the compression group, p = 0.004). Thrombosis occurred within an average of 12 ± 15 s of thrombin injection. Sedation was used in 42% of the patients undergoing compression and in none of those receiving thrombin (p = 0.001). The duration of hospitalization was significantly longer in patients undergoing compression therapy (9.8 ± 5.6 vs 5.6 ± 1.4 days, p = 0.001).**

Conclusions. **Ultrasound-guided low-dose thrombin injection appears to be more effective in reducing the need for surgical repair when used to treat iatrogenic femoral pseudoaneurysm, is better tolerated by the patients, and requires a shorter hospital stay.**

(Ital Heart J 2005; 6 (5): 384-389)

Received November 29, 2004; revision received January 25, 2005; accepted January 26, 2005.

Address:

Dr. Gian Battista Danzi

U.O. di Cardiologia
Padiglione Sacco
Ospedale Maggiore
Policlinico
Via F. Sforza, 35
20122 Milano
E-mail:gbdanzi@tin.it

Introduction

Given the increasing number and growing complexity of endovascular interventions, the incidence of vascular complications has risen[1-3]. Pseudoaneurysms (pulsating encapsulated hematomas in communication with a perforated artery) are a serious complication because they may thrombose and seldom rupture[4,5].

Persistent pseudoaneurysms were originally surgically removed[6] but, in 1991, Fellmeth et al.[7] introduced the non-invasive ultrasound-guided compression technique; however, it is often quite painful, and its reported overall success rate ranges from 47 to 100%[8-11].

An alternative and minimally invasive form of femoral artery pseudoaneurysm treatment is a direct percutaneous injection of thrombin into the aneurysmal sac[12-15]. This technique has a success rate > 95%, regardless of ongoing anticoagulation therapy[16]; however, the optimal dose of thrombin has not yet been defined. Reeder et al.[17] have recently reported that even small doses of thrombin can be effective in obliterating pseudoaneurysms.

The aim of this study was to compare the effectiveness of ultrasound compression therapy with that of low-dose thrombin injection in the treatment of femoral artery pseudoaneurysm. Considering the potential complication of thrombin use, particular care was taken to inject the lowest dose necessary to obliterate the pseudoaneurysm.

Methods

We retrospectively compared the clinical outcome of two cohorts of patients with iatrogenic femoral pseudoaneurysm treated at

our institution between 1998 and 2003. From January 1998 to November 2002, all of the pseudoaneurysms were initially treated by means of ultrasound-guided compression; persistent pseudoaneurysms were repaired using repeat ultrasound-guided compression, with surgery being reserved for cases of residual pseudoaneurysms. Between December 2002 and December 2003, the patients underwent primary thrombin injection, with surgery being considered in the case of failure.

After a clinical examination by a vascular surgeon, diagnostic ultrasound scanning was performed using an ATL HDI 5000 SonoCT (ATL Ultrasound, Bothel, WA, USA) equipped with a 7.5-MHz linear array transducer, and the length and width of the aneurysms were recorded. Once localized, the aneurysm was compressed or injected with a dilute thrombin solution. The criterion for success was the cessation of flow into the false lumen as evaluated by the vascular surgeon upon ultrasound examination. A clinical evaluation and follow-up ultrasound scan were performed 24 hours and 10 days after treatment in order to check for thrombosis or recurrence. The study was approved by our Institutional Review Board and written informed consent was obtained from each patient.

Angiographic and interventional coronary procedures. All of the diagnostic and interventional coronary procedures during the study period were performed following standardized protocols. The patients were pre-treated with aspirin (100-500 mg/day). During the diagnostic procedures, intravenous heparin was given at a dose of 2000 units regardless of the patient's body weight. The patients undergoing coronary interventions were treated with a heparin bolus of 70 U/kg, which was supplemented as necessary in order to maintain an activated clotting time of 200-250 s throughout the procedure. The heparin infusion was continued for 24 hours after the procedures only in the case of patients treated in the setting of an acute myocardial infarction. The periprocedural use of intravenous glycoprotein IIb/IIIa inhibitors was left to the discretion of the physicians, but was usually considered for diabetic patients, patients receiving multiple overlapping stents and those suffering an acute myocardial infarction. The diagnostic and interventional procedures were usually performed using 6F catheters, with the vascular sheaths being removed using manual compression when the activated clotting time was ≤ 175 s. Cardiologists checked the patients for site access complications just after the procedure and 24 hours later. In the case of groin complications, clinical and ultrasound examinations were performed by a vascular surgeon. The iatrogenic femoral pseudoaneurysm was treated by vascular surgeons, who assessed the efficacy and the complications related to the procedure.

Ultrasound-guided compression repair. A hands-off system for compression at the arterial puncture site (Femostop II Plus, Radi Medical System AB, Uppsala, Sweden) was applied for 30 min. The ability to stop flow was tested by means of a color Doppler examination. In the case of persisting flow into the false lumen, a second 60-min application was used. The decision to adopt surgical removal was taken after the failure of a third ultrasound-guided compression attempt performed 24 hours later.

Ultrasound-guided thrombin injection. Bovine thrombin (100 U/ml) (GenTrac, Inc., Middletown, WI, USA) was reconstituted in normal saline in order to obtain a solution of 100 U/ml in a 10-ml syringe attached to a 22G spinal needle. No local anesthesia was used. The pseudoaneurysm was localized by means of an ultrasound scan transducer. The needle tip was positioned in the center of the aneurysm and the thrombin solution was injected under real-time color Doppler ultrasound guidance until the lumen became opaque. The aneurysm and the femoral vessels were then examined to ensure the cessation of flow into the false lumen, and the preservation of normal flow in the native vessels. The procedure was carried out by a single operator who injected the thrombin solution while performing the ultrasound scanning. An elastic bandage was applied for 12 hours after treatment. The patients remained in bed for 24 hours after the procedure, and underwent repeat color duplex ultrasound examination on the following day, just before hospital discharge.

Statistical analysis. The continuous variables are expressed as mean values ± 1 SD, and the discrete variables as absolute values and percentages. The variables in the two groups were compared using the Student's t-test, χ^2 and Fisher's exact tests. A p value of < 0.05 was considered as statistically significant. The statistical analyses were made using the Social Science package (SPSS, SPSS Inc., Chicago, IL, USA).

Results

Between 1998 and 2003, 7951 arterial catheterizations and interventions were performed in our hospital by using the femoral approach. The incidence of femoral pseudoaneurysm was 0.7% (59 patients). From January 1998 to November 2002, ultrasound-guided compression therapy was the primary treatment method and was used in 38 patients. In December 2002, ultrasound-guided thrombin injection was introduced into our clinical practice, and has since been used in 21 consecutive patients. The clinical and procedural characteristics of the treated patients are shown in tables I and II. The mean age of the patients was 70 ± 13 years. The majority of the pseudoaneurysms were caused by interventional coronary procedures (76%). Both groups had similar demographic and procedural characteristics, and similarly sized aneurysms (Tables I and II).

Table I. Demographic characteristics of the 59 patients.

	Compression therapy (n=38)	Thrombin injection (n=21)	p
Age (years)	69 ± 11	74 ± 13	0.12
Males	18 (47%)	10 (48%)	0.44
Body surface area (m^2)	1.74 ± 0.2	1.77 ± 0.2	0.58
Weight (kg)	69 ± 14	72 ± 16	0.46
Diabetes mellitus	5 (13%)	8 (38%)	0.49
Total cholesterol > 200 mg/dl	21 (55%)	12 (57%)	0.83
Hypertension	22 (58%)	12 (57%)	0.40
Current smokers	8 (21%)	3 (14%)	0.44
Family history of CAD	25 (66%)	14 (66%)	0.28

CAD = coronary artery disease.

Table II. Clinical and procedural characteristics.

	Compression therapy (n=38)	Thrombin injection (n=21)	p
Pseudoaneurysm size (cm)			
Length	3.5 ± 3.3	3.2 ± 2.8	0.72
Width	3.2 ± 3.1	3.5 ± 3.2	0.73
Diagnostic catheterization	8 (21%)	6 (29%)	0.74
Angioplasty	30 (79%)	15 (71%)	0.74
Sheath size (F)	6.1 ± 0.5	6.2 ± 0.6	0.50
Anticoagulation	12 (32%)	6 (29%)	0.96
GP IIb/IIIa administration	19 (50%)	9 (43%)	0.19
Time to compression (min)	36 ± 23	–	–
Amount of thrombin (U/ml)	–	185 ± 95	
100-199	–	8	
200-299	–	6	
300-400	–	7	
Thrombosis time (s)	–	12 ± 15	
Blood transfusion	11 (29%)	1 (5%)	0.06
Duration of hospitalization (days)	9.8 ± 5.6	5.6 ± 1.4	0.001

GP = glycoprotein.

Forty-five pseudoaneurysms were classified as simple (single lobe), and 4 as complex (at least two lobes and a single neck to the native vessel). There was no between-group difference in the post-procedure treatment (Table II). All of the patients received oral antiplatelet agents at the time of treatment: 31% were systemically anticoagulated with heparin, whereas 47% received periprocedural glycoprotein IIb/IIIa inhibitors. Twelve patients (11 undergoing compression therapy and 1 receiving a thrombin injection) required blood transfusion because of a significant decrease in hematocrit levels after the procedure. The time between the interventional procedure and the first treatment of the pseudoaneurysm was 2.1 ± 0.5 days.

Femoral compression was successful at the first attempt in 21/38 patients (55%). Three more pseudoaneurysms were successfully treated during repeat sessions (two attempts in 2 patients, and three attempts in 1), leading to an overall success rate of 63%. The patients who underwent successful treatment required an average of 36 min of compression (range 30-150 min).

The remaining 14 patients with persistent aneurysms (37%) underwent surgical repair under general anesthesia. No intra- or postoperative complications were observed in these patients. The administration of unfractionated heparin or a glycoprotein IIb/IIIa inhibitor was not statistically different in the patients undergoing successful or failed compression therapy.

Twenty-one consecutive patients received primary thrombin injection therapy, which was successful in all cases (Fig. 1). Thrombosis occurred within 12 ± 15 s of the injection, and required an average dose of 185 ± 95 U/ml (range 100-400 U/ml). No complications related to thrombin injections were observed. There was no statistically significant relationship between the amount of thrombin injected and the size or classification of the aneurysm. Anticoagulation status or the use of glycoprotein IIb/IIIa inhibitors did not affect the ef-

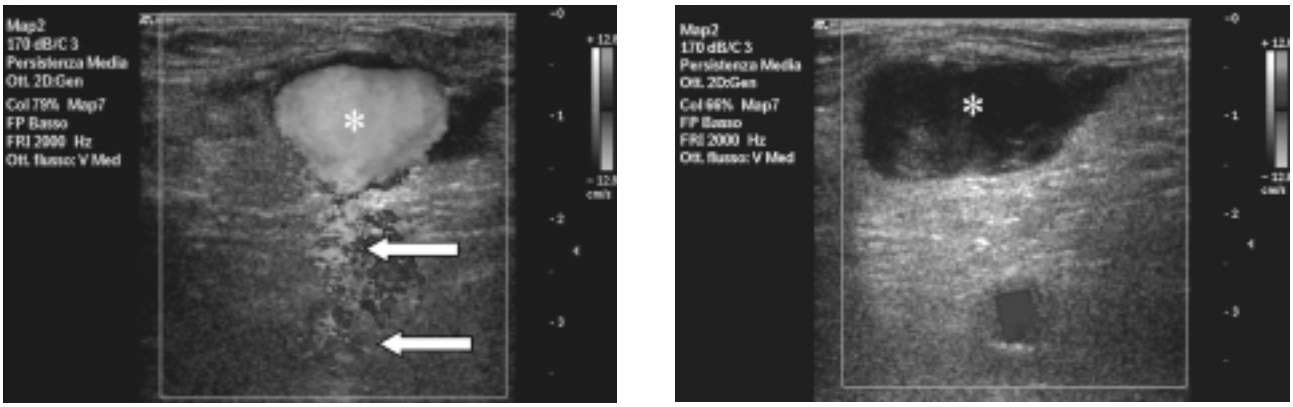

Figure 1. Left panel: *color duplex ultrasound view of the pulsating hematoma (*), its neck* (arrow) *and the relationship with the femoral artery* (arrow). Right panel: *complete obliteration of the cavity (*).*

ficacy of the procedure. None of the patients in the thrombin group required sedation compared with 42% in the compression group (p = 0.001). Blood cell transfusions were needed more frequently in patients treated with compression (29 vs 5%, p = 0.06). The mean duration of hospitalization was 8.6 ± 6.9 days, but it was significantly shorter in those treated with thrombin (5.6 ± 1.4 vs 9.8 ± 5.6 days, p = 0.001). The results of the ultrasound examinations performed 10 days after discharge were completely normal (95%) or showed some residual hematoma, but without any recurrence of pseudoaneurysm. Nineteen of the 21 patients (90%) treated with thrombin injection had a clinical and ultrasound follow-up at 6 months. No recurrence or late groin problems related to treatment were noted.

Discussion

Percutaneous thrombin injection therapy is a very promising treatment for iatrogenic femoral artery pseudoaneurysm[12-21]. This study confirms that the technique is safe, less time-consuming and more effective than ultrasound-guided compression; all of the patients underwent successful treatment even with a low dose of thrombin (185 ± 95 U/ml, range 100-400 U/ml).

The majority of iatrogenic pseudoaneurysms need to be treated in order to avoid the inherent risk of rupture, hemorrhage and thrombosis of the native artery. Surgical repair was the only option for definitive treatment for many years[6] but, over the last decade, ultrasound-guided compression has been introduced into clinical practice of many interventional laboratories as primary treatment, and surgery has been considered only in the case of failure[7-11]. Ultrasound-guided compression treatment is limited by the fact that is painful and time consuming, and has a success rate that does not exceed 75% even after repeated attempts. Hajarizadeh et al.[22] reported that the initial failure of this approach was directly related to the inability of the patient to tolerate the pain; for this reason their procedures were performed by using sedation.

The efficacy of compression in the setting of ongoing anticoagulation treatment with heparin and/or warfarin is still debated. Small, uncontrolled studies have reported that anticoagulation is an independent predictor of failure[7-11], but Dean et al.[23] found that the only factor influencing success was the size of the pseudoaneurysm in a large series of patients undergoing treatment with heparin and/or warfarin. In our experience, the success rate of compression treatment after multiple attempts was 63%; the result of the procedure was not affected by anticoagulation with heparin, the use of glycoprotein IIb/IIIa inhibitors, or the size of the aneurysm.

Bovine thrombin is a plasma-thrombin concentrate that has been used topically to control hemorrhaging for the past 50 years in a variety of surgical specialties. After the reports of Liau et al.[13] and Kang et al.[14] showing the safety and effectiveness of percutaneous thrombin injection for the treatment of false aneurysms, we introduced the technique into our clinical practice at a lower thrombin dose than that previously used (Table III)[13-17,19-21]. The success rate is encouraging, and there have been no complications. Remarkable advantages of this technique relate to the fact that it is less painful compared to other approaches, and no particular learning curve is required when performed in specialized cardiovascular centers.

The choice of using a brisk, low-dose injection was based on various considerations: it is well known that iatrogenic native artery thrombosis, hypotension, bradycardia and fever are all potential reactions to exposure to bovine thrombin; furthermore, it seems that these complications can be triggered by a higher thrombin dose[14,20,24-26]. However, the most serious complication of thrombin injections seems to be the inadvertent occlusion of healthy vessels; these patients can be successfully managed by means of thrombolysis, thrombectomy or a bypass[26].

Table III. Average dose of injected thrombin and procedural success rate in patients with pseudoaneurysm.

Study	No. patients	Average thrombin dose (U/ml)	Range (U/ml)	Success rate (%)
Liau et al.[13], 1997	5	1000	–	100
Kang et al.[14], 1998	21	1333	1000-2000	95
Taylor et al.[19], 1999	23	300	100-600	93
La Perna et al.[15], 2000	70	1150	–	94
Reeder et al.[17], 2001	23	192	50-450	100
Paulson et al.[16], 2001	114	306	50-1600	96
Calton et al.[21], 2001	54	1500	–	94
Gorge and Kuntz[20], 2003	23	895	100-2000	96

In an effort to improve the technique and avoid thrombotic complications, Grewe et al.[18] suggested the use of contrast ultrasound-guided thrombin injection in order to define the characteristics of the pseudoaneurysms more precisely, especially those with larger connections in which the risk of thrombin escape is higher. Loose and Haslam[27] successfully treated 13 patients by injecting fibrin tissue adhesive under ultrasound guidance after advancing a vascular catheter with an occlusive balloon into the femoral artery in order to arrest flow to the pseudoaneurysm. Hamraoui et al.[28] used percutaneous injection of biodegradable bovine collagen. The major advantage of this technique lies in the physical-chemical properties of the collagen; the fact that it consists of long paste fibers, reduces the risk of migration in the femoral vessel, particularly when a large connection is present.

As suggested by other authors[17,26], we prefer injecting a low dose of thrombin and keep the patients in bed for 24 hours with an elastic bandage. Using this approach, we have achieved complete occlusion of the pseudoaneurysm (documented by means of ultrasound examinations after 24 hours and 10 days), without any procedure-related complications.

In comparison with ultrasound-guided compression, thrombin injection treatment seems to be cost-saving. Taylor et al.[19] analyzed the costs related to vascular laboratory resource consumption and operating room use, and demonstrated an average per-patient reduction of $494 in favor of thrombin injection. Although we did not take into account the costs of the procedures, the duration of hospitalization was significantly shorter among patients treated with thrombin (9.8 ± 5.6 vs 5.6 ± 1.8 days, $p = 0.001$), and this has a direct impact on total hospital expenditure.

Study limitations. This study has a number of limitations related to its relatively small sample size and non-randomized nature. However, the protocols and guidelines for coronary angiography and coronary intervention procedures used in our laboratory permitted us to enroll two homogeneous samples of patients. The study was not powered to detect differences in the impact of some parameters (such as size and characteristics of the aneurysm, or the use of different medications) on the two treatment strategies, nor was it designed to test different thrombin doses. All of these points should be carefully addressed in future controlled studies.

In conclusion, our results confirm that ultrasound-guided low-dose thrombin injection for the treatment of iatrogenic femoral pseudoaneurysm seems to be more effective in reducing the need for surgical repair, is better tolerated by patients, and requires a shorter hospital stay than ultrasound-guided compression. Even when a low thrombin dose is used, anticoagulation status or the use of glycoprotein IIb/IIIa inhibitors does not affect the efficacy of the procedure.

References

1. Rosenfield K, Goldstein JA, Safian RD. Medical and peripheral vascular complications. In: Safian RD, Freed MS, eds. The manual of interventional cardiology. 3rd edition. Royal Oak, MI: Physicians' Press, 2001: 467-507.
2. Bredlau CE, Roubin GS, Leimgruber PP, Douglas JS Jr, King SB 3rd, Gruentzig AR. In-hospital morbidity and mortality in patients undergoing elective coronary angioplasty. Circulation 1985; 72: 1044-52.
3. Oweida SW, Roubin GS, Smith RB 3rd, Salam AA. Post-catheterization vascular complications associated with percutaneous transluminal coronary angioplasty. J Vasc Surg 1990; 12: 310-5.
4. Grossman W. Complications of cardiac catheterization: incidence, causes, and prevention. In: Grossman W, Baim DS, eds. Cardiac catheterization, angiography, and intervention. 4th edition. Philadelphia, PA: Lea and Febiger, 1991: 28-46.
5. Messina LM, Brothers TE, Wakefield TW, et al. Clinical characteristics and surgical management of vascular complications in patients undergoing cardiac catheterization: interventional versus diagnostic procedures. J Vasc Surg 1991; 13: 593-600.
6. Skillman JJ, Kim D, Baim DS. Vascular complications of percutaneous femoral cardiac interventions: incidence and operative repair. Arch Surg 1988; 123: 1207-12.
7. Fellmeth BD, Roberts AC, Bookstein JJ, et al. Postangiographic femoral artery injuries: nonsurgical repair with US-guided compression. Radiology 1991; 178: 671-5.
8. Feld R, Patton GM, Carabasi RA, Alexander A, Merton D, Needleman L. Treatment of iatrogenic femoral artery in-

juries with ultrasound-guided compression. J Vasc Surg 1992; 16: 832-40.
9. Cox GS, Young JR, Gray BR, Grubb MW, Hertzer NR. Ultrasound-guided compression repair of post-catheterization pseudoaneurysms: results of treatment in one hundred cases. J Vasc Surg 1994; 19: 683-6.
10. Coley BD, Roberts AC, Fellmeth BD, Valji K, Bookstein JJ, Hye RJ. Postangiographic femoral artery pseudoaneurysms: further experience with US-guided compression repair. Radiology 1995; 194: 307-11.
11. Agarwal R, Agarwal SK, Roubin GS, et al. Clinically guided closure of femoral arterial pseudoaneurysms complicating cardiac catheterization and coronary angioplasty. Cathet Cardiovasc Diagn 1993; 30: 96-100.
12. Cope C, Zeit R. Coagulation of aneurysms by direct percutaneous thrombin injection. AJR Am J Roentgenol 1986; 147: 383-7.
13. Liau CS, Ho FM, Chen MF, Lee YT. Treatment of iatrogenic femoral artery pseudoaneurysm with percutaneous thrombin injection. J Vasc Surg 1997; 26: 18-23.
14. Kang SS, Labropoulos N, Mansour MA, Baker WH. Percutaneous ultrasound guided thrombin injection: a new method for treating postcatheterization femoral pseudoaneurysms. J Vasc Surg 1998; 27: 1032-8.
15. La Perna L, Olin JW, Goines D, Childs MB, Ouriel K. Ultrasound-guided thrombin injection for the treatment of postcatheterization pseudoaneurysms. Circulation 2000; 102: 2391-5.
16. Paulson EK, Nelson RC, Mayes CE, Sheafor DH, Sketch MH, Kliewer MA. Sonographically guided thrombin injection of iatrogenic femoral pseudoaneurysms: further experience of a single institution. AJR Am J Roentgenol 2001; 177: 309-16.
17. Reeder SB, Widlus DM, Lazinger M. Low-dose thrombin injection to treat iatrogenic femoral artery pseudoaneurysms. AJR Am J Roentgenol 2001; 177: 595-8.
18. Grewe PH, Deneke T, Fadgyas T, et al. Minimally invasive percutaneous contrast-ultrasound guided thrombin occlusion of iatrogenic pseudoaneurysm. Z Kardiol 2001; 90: 737-44.
19. Taylor BS, Rhee R, Muluk S, et al. Thrombin injection versus compression of femoral artery pseudoaneurysms. J Vasc Surg 1999; 30: 1052-9.
20. Gorge G, Kunz T. Thrombin injection for treatment of false aneurysms after failed compression therapy in patients on full-dose antiplatelet and heparin therapy. Catheter Cardiovasc Interv 2003; 58: 505-9.
21. Calton WC, Franklin DP, Elmore JR, Han DC. Ultrasound-guided thrombin injection is a safe and durable treatment for femoral pseudoaneurysms. Vasc Surg 2001; 35: 379-83.
22. Hajarizadeh H, LaRosa CR, Cardullo P, Rohrer MJ, Cutler BS. Ultrasound-guided compression of iatrogenic femoral pseudoaneurysm: failure, recurrence, and long-term results. J Vasc Surg 1995; 22: 425-33.
23. Dean SM, Olin JW, Piedmonte M, Grubb M, Young JR. Ultrasound-guided compression closure of postcatheterization pseudoaneurysms during current anticoagulation: a review of seventy-seven patients. J Vasc Surg 1996; 23: 28-35.
24. Vignolo-Scalone WH, Vignolo-Puglia WH, Kitchens CS. Microvascular alterations in thrombin-induced experimental disseminated intravascular coagulation in the dog. Angiology 1984; 35: 261-8.
25. Pope M, Johnston KW. Anaphylaxis after thrombin injection of a femoral pseudoaneurysm: recommendations for prevention. J Vasc Surg 2000; 32: 190-1.
26. Sadiq S, Ibrahim W. Thromboembolism complicating thrombin injection of femoral artery pseudoaneurysm: management with intraarterial thrombolysis. J Vasc Interv Radiol 2001; 12: 633-6.
27. Loose HW, Haslam PJ. The management of peripheral arterial aneurysms using percutaneous injection of fibrin adhesive. Br J Radiol 1998; 71: 1255-9.
28. Hamraoui K, Ernst SM, van Dessel PF, et al. Efficacy and safety of percutaneous treatment of iatrogenic femoral artery pseudoaneurysm by biodegradable collagen injection. J Am Coll Cardiol 2002; 39: 1297-304.